

# Early risk factors for transplant coronary artery disease and cardiac allograft failure

Carlos A. Labarrere

Methodist Research Institute, Clarian Health Partners (Methodist, Indiana University, and Riley Hospitals), Indianapolis, IN, USA

(Ital Heart J 2001; 2 (Suppl 3): 26S-28S)

© 2001 CEPI Srl

Address:

Carlos A. Labarrere, MD,  
FACC

Methodist Research  
Institute  
Clarian Health Partners  
Methodist, Indiana  
University, and  
Riley Hospitals  
1701 N. Senate Boulevard  
Indianapolis, IN 46202  
USA  
E-mail:  
clabarrere@clarian.com

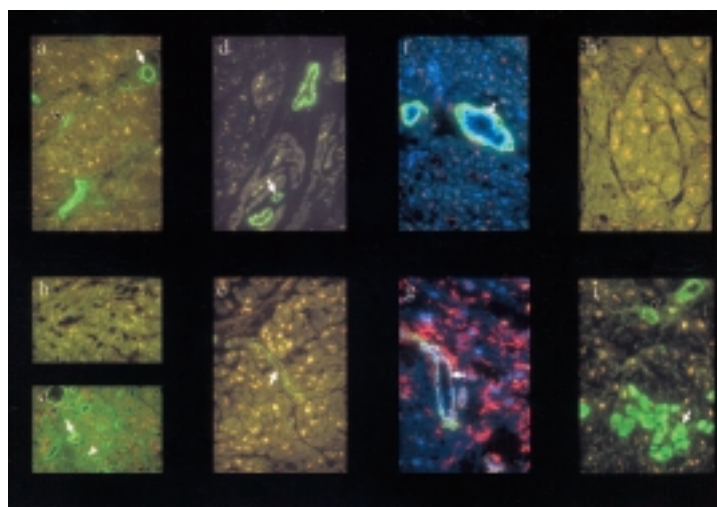
The success of heart transplantation is directly associated with the status of the cardiac microvasculature and with the development of a transplant-associated vasculopathy known as transplant coronary artery disease (CAD)<sup>1</sup>. The development of transplant CAD is a serious complication and a major threat to the survival of the cardiac allograft because the disease affects not only the major epicardial arteries but also the intramyocardial arteries<sup>1-3</sup>. Most importantly, the disease not only compromises the arterial tree but also the capillary network and the venous system, indicating that this is a diffuse panvascular disease<sup>1-3</sup>.

In recent years, contributions have been made to understanding the pathogenetic mechanisms involved in the development of the disease<sup>1-10</sup>. The early identification of allografts prone to developing transplant CAD is one of the major tasks in heart transplantation research. This is particularly important because the disease develops within the first year following transplantation in a significant number of recipients, and in these recipients the survival of the allografts is significantly shortened<sup>4,11</sup>.

During the past several years, we were able to identify within the cardiac microvasculature risk factors for subsequent transplant CAD and cardiac allograft failure<sup>1-10</sup>. All these microvascular changes are associated with a lack of thromboresistance and development of a prothrombogenic microvasculature (Fig. 1) and can be identified within the first week(s) of the transplant procedure<sup>1-10</sup>. Indeed, the identification of fibrin deposits within the cardiac microvasculature during the first week(s) following transplantation is directly associated with the long-term outcome of the al-

lografts<sup>5,7</sup>. The presence of fibrin within the cardiac microvasculature in the first week(s) after transplantation is associated with the subsequent development of transplant CAD and cardiac allograft failure<sup>5,7</sup>. The significance of these findings is even more important when we consider that the presence of microvascular fibrin is frequently associated with myocardial cell damage and cell death mirrored in circulation by the detection of increasing levels of serum cardiac troponin I<sup>7</sup>.

Although the mechanism(s) involved in the deposition of microvascular fibrin is(are) not known, several possibilities have been suggested. One such possibility is that these changes are the consequence of ischemia and reperfusion<sup>1-3</sup>. Indeed, ischemia and reperfusion can promote the development of a prothrombogenic microvasculature. Fibrin can be deposited within the cardiac allograft microvasculature as a consequence of a) endothelial activation which promotes expression of tissue factor on endothelial plasma membranes<sup>4,6</sup>; b) depletion of microvascular tissue plasminogen activator, which disallows the activation of the fibrinolytic pathway and the subsequent removal of deposited fibrin<sup>9</sup>; and/or c) lack of microvascular antithrombin, which disallows the impediment of further microvascular fibrin deposition<sup>8</sup>. All these microvascular changes are associated with the presence of a prothrombogenic microvasculature. Each of these changes – and not the presence of cellular rejection episodes – is an independent risk factor for subsequent transplant CAD (Table I). Although each prothrombogenic risk factor is important individually, the importance of their cumulative effect and their interrelatedness is demonstrated by



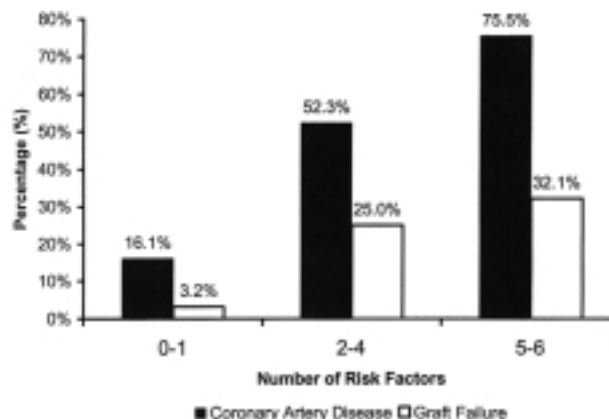
**Figure 1.** Immunohistochemical findings of a prothrombogenic microvasculature. A thromboresistant microvasculature is characterized by a) antithrombin in arterial smooth muscle cells and intima (arrow) and venous endothelium (open arrow); d) presence of tissue plasminogen activator in arteriolar smooth muscle cells (arrow); f) absence of intercellular adhesion molecule-1 and human leukocyte antigen (HLA)-DR on arterial and arteriolar endothelium (arrow); and h) absence of fibrin. A prothrombogenic microvasculature is characterized by b) absence of vascular antithrombin; e) depletion of arteriolar tissue plasminogen activator from arteriolar smooth muscle cells (arrow); g) presence of arterial and arteriolar endothelial intercellular adhesion molecule-1 and HLA-DR (arrow); and i) presence of fibrin within microvasculature (open arrow) and myocardial cells (arrow). Allografts that are initially prothrombogenic and regain thromboresistance recover arterial (arrow in c) and venous (open arrow in c) vascular antithrombin and develop unusual capillary antithrombin reactivity (arrowhead in c). Panels f and g show a triple-antibody technique with monoclonal antibodies to HLA-DR (red), smooth muscle-specific  $\alpha$ -actin (green), and von Willebrand factor (blue) to localize arterial and arteriolar endothelial reactivity. Original magnification  $\times 400$ .

**Table I.** Relationship between early risk factors and risk of subsequent coronary artery disease in cardiac allografts.

Variables	Hazard ratio*	95% CI	p
Myocardial fibrin	6.9	3.6-13.0	< 0.0001
Detectable serum cardiac troponin I	1.8	1.1-2.9	0.02
Depleted arteriolar tissue plasminogen activator	4.9	2.7-8.8	< 0.0001
Arterial endothelial ICAM-1/HLA-DR	6.1	3.2-11.5	< 0.0001
Elevated serum soluble ICAM-1	2.7	1.3-5.6	0.009
Vascular antithrombin			
Negative antithrombin	2.6	1.4-4.7	0.004
Capillary antithrombin	2.0	1.2-3.4	0.007
Cellular rejection episodes			
Grades 1 and 2	1.3	0.8-2.1	0.25
Grades 3 and 4	1.2	0.6-2.2	0.65

CI = confidence interval; HLA-DR = human leukocyte antigen-DR; ICAM-1 = intercellular adhesion molecule-1. \* hazard ratios and 95% CI from Cox proportional hazard regression.

the increased risk for CAD and allograft failure as the number of early risk factors increases<sup>1</sup> (Fig. 2). The association between prothrombogenic factors within the cardiac allograft microvasculature and subsequent transplant CAD and allograft failure, and the lack of association between cellular rejection and subsequent transplant CAD and failure, suggests that therapies must target mainly the allograft microvasculature and not just the recipients' immune cells in order to preserve thromboresistance. Whatever the therapy(ies) used to reduce the incidence of transplant CAD or failure in cardiac transplantation, they must be introduced during the peritransplant period because risk factors associated with the development of the disease and subsequent failure appear immediately after the transplant procedure.



**Figure 2.** Nonimmunologic risk factors and coronary artery disease and failure. An increasing number of nonimmunologic risk factors within an allograft in the first week(s) after transplantation is associated with increased risk for developing coronary artery disease and graft failure.

## References

1. Labarrere CA, Nelson DR, Park JW. Pathologic markers of allograft arteriopathy: insight into the pathophysiology of cardiac allograft chronic rejection. *Curr Opin Cardiol* 2001; 16: 110-7.
2. Labarrere CA. Relationship of fibrin deposition in microvasculature to outcomes in cardiac transplantation. *Curr Opin Cardiol* 1999; 14: 133-9.
3. Labarrere CA. Anticoagulation factors as predictors of transplant-associated coronary artery disease. *J Heart Lung Transplant* 2000; 19: 623-33.
4. Labarrere CA, Nelson DR, Miller SJ, et al. Value of serum-soluble intercellular adhesion molecule-1 for the noninvasive risk assessment of transplant coronary artery disease, posttransplant ischemic events, and cardiac graft failure. *Circulation* 2000; 102: 1549-55.
5. Labarrere CA, Nelson DR, Faulk WP. Myocardial fibrin deposits in the first month after transplantation predict subsequent coronary artery disease and graft failure in cardiac allograft recipients. *Am J Med* 1998; 105: 207-13.
6. Labarrere CA, Nelson DR, Faulk WP. Endothelial activation and development of coronary artery disease in transplanted human hearts. *JAMA* 1997; 278: 1169-75.
7. Labarrere CA, Nelson DR, Cox CJ, et al. Cardiac-specific troponin I levels and risk of coronary artery disease and graft failure following heart transplantation. *JAMA* 2000; 284: 457-64.
8. Labarrere CA, Torrey RJ, Nelson DR, et al. Vascular antithrombin and clinical outcome in heart transplant patients. *Am J Cardiol* 2001; 87: 425-31.
9. Labarrere CA, Pitts D, Nelson DR, et al. Vascular tissue plasminogen activator and the development of coronary artery disease in heart-transplant recipients. *N Engl J Med* 1995; 333: 1111-6.
10. Labarrere CA, Nelson DR. Role of hemostasis, anticoagulation, fibrinolysis and endothelial activation. In: Rose ML, ed. *Transplant-associated coronary artery vasculopathy*. Georgetown, TX: Landes Bioscience, 2001: 90-117.
11. Costanzo MR, Naftel DC, Pritzker MR, et al. The Cardiac Transplant Research Database. Heart transplant coronary artery disease detected by coronary angiography: a multi-institutional study of preoperative donor and recipient risk factors. *J Heart Lung Transplant* 1998; 17: 744-53.