

Coronary vasodilator reserve in left ventricular hypertrophy

Paolo G. Camici

MRC Clinical Sciences Centre, Imperial College School of Medicine, Hammersmith Hospital, London, UK

(Ital Heart J 2001; 2 (Suppl 3): 20S-22S)

© 2001 CEPI Srl

Address:

Prof. Paolo G. Camici

*MRC Clinical
Sciences Centre
Imperial College School
of Medicine
Hammersmith Hospital
Du Cane Road
London W12 0NN
UK
E-mail: paolo.camici@
csc.mrc.ac.uk*

Cardiac hypertrophy is a morphological adaptive increase in myocardial mass in response to chronic work overload and is a common clinical finding affecting 23% of men and 33% of women over the age of 59 years¹. Pressure or volume overload on the myocardium results in an increase in myocardial wall stress and hypertrophy may be seen as an attempt to normalise wall stress and oxygen demand^{2,3}. The increased myocardial mass requires an increase in coronary blood flow to maintain function. Indeed, ventricular hypertrophy may be associated with myocardial ischaemia even with angiographically normal coronary arteries⁴⁻⁶. Left ventricular hypertrophy (LVH) significantly increases the risk of myocardial infarction, congestive heart failure and sudden cardiac death⁷⁻⁹. It is also associated with a greater prevalence of cardiac arrhythmias¹⁰ and is an important risk factor for cardiac morbidity and mortality^{11,12}.

Coronary vasodilator reserve in left ventricular hypertrophy

The coronary vasodilator reserve (CVR), defined as the ratio of myocardial blood flow (MBF) during near maximal hyperaemia to baseline MBF, is reduced in LVH due to hypertension¹³, aortic stenosis¹⁴, aortic regurgitation¹⁵, supraaortic stenosis and hypertrophic cardiomyopathy¹⁶ and in experimental models of LVH¹⁷⁻²⁰ (Fig. 1). The reduced CVR limits the ability of hypertrophied hearts to meet the metabolic requirements when demand is increased. Despite normal myocardial oxygen consumption²⁰ and myocardial perfusion per unit mass^{21,22} at rest, the hypertrophied heart is more vulnerable to ischaemia²³⁻²⁶.

Experiments in animals^{3,23} have demonstrated that the impairment of CVR is more marked in the subendocardial layers of the left ventricle, with some evidence of an alteration in the normal subendocardial-subepicardial distribution of perfusion during near maximal vasodilatation in patients with hypertrophic cardiomyopathy²⁷. More recently¹⁴ we have demonstrated that CVR is impaired in patients with LVH secondary to aortic stenosis and that the impairment correlates with the severity of the transvalvular gradient. In addition, as the gradient increases, subendocardial CVR becomes progressively more impaired than subepicardial CVR (Fig. 2).

Effect of left ventricular hypertrophy regression on the impairment of coronary vasodilator reserve

Experimental studies have reported that antihypertensive treatment of spontaneously hypertensive rats reduces LVH²⁸⁻³¹ with improvements in left ventricular compliance and reduced vulnerability to ischaemia although CVR remained impaired³². In contrast, other studies have demonstrated some recovery in coronary vascular morphology^{33,34} and CVR³⁵ with regression of experimental hypertrophy. Reduction in echocardiographically measured left ventricular mass has been observed clinically after treatment³⁶⁻⁴³ in patients with hypertension. Regression of LVH does occur following aortic valve replacement⁴⁴ but may remain incomplete in 50% of such patients⁴⁵. In contrast to the intense interest in regression of left ventricular mass, few studies have examined whether this is accompanied by reversal of the pathophysiological effects of LVH. Pre-




Figure 1. Myocardial blood flow measured by position emission tomography with oxygen-15 labelled water at rest and during near-maximal coronary vasodilatation (dipyridamole 0.56 mg/kg) in normal subjects (left panel), in patients with hypertrophic cardiomyopathy (HC, middle panel), and in patients with left ventricular hypertrophy (LVH) secondary to hypertension or aortic stenosis (right panel). Note the significant reduction in hyperaemic blood flow both in HC and LVH compared to normals.

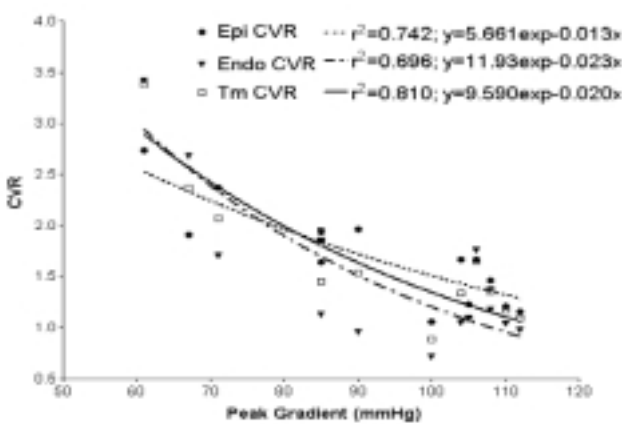


Figure 2. Correlation of coronary vasodilator reserve (CVR) with aortic valve gradient. Relationship between full thickness (transmural-Tm), subendocardial (Endo) and subepicardial (Epi) CVR (measured by positron emission tomography with oxygen-15 labelled water at rest and during near-maximal coronary vasodilatation with dipyridamole 0.56 mg/kg) and severity of aortic valve gradient in patients with aortic stenosis. Note the progressive decline of CVR with the increase of the gradient severity particularly in the subendocardial layers.

liminary results from our study in patients with aortic stenosis and LVH show that reduction in left ventricular mass following aortic valve replacement is associated with a marked improvement of overall CVR¹⁴. It is unclear whether similar changes occur with regression of LVH in hypertension. One study has demonstrated an improvement in CVR with antihypertensive treatment⁴⁶, although it remains to be established whether regression of LVH correlates with improvement in CVR.

References

1. Savage DD, Garrison RJ, Kannel WB, et al. The spectrum of left ventricular hypertrophy in a general population sample: the Framingham study. *Circulation* 1987; 75 (Suppl 1): I26-I33.
2. Kuhn H. The definition of ventricular hypertrophy. *Eur Heart J* 1982; 3 (Suppl A): 5-8.

3. Chilian WM, Marcus ML. Coronary vascular adaptations to myocardial hypertrophy. *Annu Rev Physiol* 1987; 49: 477-87.
4. Pichard AD, Gorlin R, Smith H, Ambrose J, Meller J. Coronary flow studies in patients with left ventricular hypertrophy of the hypertensive type. Evidence for an impaired coronary vascular reserve. *Am J Cardiol* 1981; 47: 547-53.
5. Opherk D, Mall G, Zebe H, et al. Reduction of coronary reserve: a mechanism for angina pectoris in patients with arterial hypertension and normal coronary arteries. *Circulation* 1984; 69: 1-7.
6. Marcus ML, Doty DB, Hiratzka LF, Wright CB, Eastham CL. A mechanism for angina pectoris in patients with aortic stenosis and normal coronary arteries. *N Engl J Med* 1982; 307: 1362-7.
7. Kannel WB. Prevalence and natural history of electrocardiographic left ventricular hypertrophy. *Am J Med* 1983; 75 (Suppl 3A): 4-11.
8. Kannel WB. Left ventricular hypertrophy as a risk factor for arterial hypertension. *Eur Heart J* 1992; 13 (Suppl D): 82-8.
9. Levy D, Garrison RJ, Savage DD, Kannel WB, Castelli WP. Prognostic implications of echocardiographically determined left ventricular mass in the Framingham Heart Study. *N Engl J Med* 1990; 322: 1561-6.
10. Levy D, Anderson KM, Savage DD, Balkus SA, Kannel WB, Castelli WP. Risk of ventricular arrhythmias in left ventricular hypertrophy: the Framingham Heart Study. *Am J Cardiol* 1987; 60: 560-5.
11. Cooper RS, Simmons BE, Castaner A, Santhanam V, Ghali J, Mar M. Left ventricular hypertrophy is associated with worse survival independent of ventricular function and number of coronary arteries severely narrowed. *Am J Cardiol* 1990; 65: 441-5.
12. Gordon T, Kannel WB. Premature mortality from coronary heart disease. The Framingham study. *JAMA* 1971; 215: 1617-25.
13. Choudhury L, Rosen SD, Patel D, Nihoyannopoulos P, Camici PG. Coronary vasodilator reserve in primary and secondary left ventricular hypertrophy. *Eur Heart J* 1997; 18: 108-16.
14. Rajappan K, Rimoldi O, Ariff B, Pennell DJ, Sheridan DJ, Camici PG. The impairment of coronary vasodilator reserve is related to the severity of aortic stenosis. (abstr) *Circulation* 2000; 102 (Suppl 2): II-785.
15. Pichard AD, Smith H, Holt J. Coronary vascular reserve in left ventricular hypertrophy secondary to chronic aortic regurgitation. *Am J Cardiol* 1983; 51: 315-20.

16. Radvan J, Choudhury L, Sheridan DJ, Camici PG. Coronary vasodilator reserve in elite athletes with left ventricular hypertrophy compared to patients with hypertrophic cardiomyopathy. *Am J Cardiol* 1997; 80: 1621-3.
17. Jeremy RW, Fletcher PJ, Thompson J. Coronary pressure-flow relations in hypertensive left ventricular hypertrophy. Comparison of intact autoregulation with physiological and pharmacological vasodilation in the dog. *Circ Res* 1989; 65: 224-36.
18. Isoyama S, Ito I, Kurcha M, Takishima T. Complete reversibility of physiological coronary vascular abnormalities in hypertrophied hearts produced by pressure overload in the rat. *J Clin Invest* 1989; 84: 288-94.
19. O'Gorman DJ, Thomas P, Turner MA, Sheridan DJ. Investigation of impaired coronary vasodilator reserve in the guinea pig heart with pressure-induced hypertrophy. *Eur Heart J* 1992; 13: 697-703.
20. O'Gorman DJ, Sheridan DJ. Abnormalities of the coronary circulation associated with left ventricular hypertrophy. *Clin Sci* 1991; 81: 703-13.
21. Malik AB, Abe T, O'Kane H, Geha AS. Cardiac function, coronary flow and oxygen consumption in stable left ventricular hypertrophy. *Am J Physiol* 1973; 225: 186-91.
22. Holtz J, Restorff W, Bard P, Barssenge E. Transmural distribution of myocardial blood flow and coronary reserve in canine left ventricular hypertrophy. *Basic Res Cardiol* 1977; 72: 286-92.
23. Vatner SF, Shannon R, Hittinger L. Reduced subendocardial coronary reserve. A potential mechanism for impaired diastolic function in the hypertrophied and failing heart. *Circulation* 1990; 81 (Suppl III): III8-III14.
24. Buser PT, Wagner S, Wu ST, et al. Verapamil preserves myocardial performance and energy metabolism in left ventricular hypertrophy following ischemia and reperfusion. Phosphorus 31 magnetic resonance spectroscopy study. *Circulation* 1989; 80: 1837-45.
25. Nakano K, Corin WJ, Spaan JFJ, Biederman RWW, Denslow S, Carabello BA. Abnormal subendocardial blood flow in pressure overload hypertrophy is associated with pacing-induced subendocardial dysfunction. *Circ Res* 1989; 65: 1555-64.
26. McAinsh AM, Turner MA, O'Hare D, et al. Cardiac hypertrophy impairs recovery from ischaemia because there is a reduced reactive hyperaemic response. *Cardiovasc Res* 1995; 30: 113-21.
27. Gistri R, Cecchi F, Choudhury L, et al. Effect of verapamil on absolute myocardial blood flow in hypertrophic cardiomyopathy. *Am J Cardiol* 1994; 74: 363-8.
28. Kimpara T, Okabe M, Nishimura H, Hayashi T, Imamura K, Kawamura K. Ultrastructural changes during myocardial hypertrophy and its regression: long-term effects of nifedipine in adult spontaneously hypertensive rats. *Heart Vessels* 1997; 12: 143-51.
29. Chevalier B, Callens-El-Amrani F, Heymes C, Swynghedauw B. The molecular basis of regression of cardiac hypertrophy. *Am J Cardiol* 1994; 73: 10C-17C.
30. Kohya T, Yokoshiki H, Tohse N, et al. Regression of left ventricular hypertrophy prevents ischaemia-induced lethal arrhythmias: beneficial effect of angiotensin II blockade. *Circ Res* 1995; 76: 892-9.
31. Okamoto K, Abe M, Hanada T. Effect of regression of cardiac hypertrophy on ischaemic myocardial damage in spontaneously hypertensive rats. *Jpn Circ J* 1993; 57: 147-60.
32. Brilla CG, Janicki JS, Weber KT. Impaired diastolic function and coronary reserve in genetic hypertension. Role of interstitial fibrosis and medial thickening of intramyocardial coronary arteries. *Circ Res* 1991; 69: 107-15.
33. Vogt M, Motz W, Stauer BE. Long-term treatment in arterial hypertension for protecting myocardium. *Basic Res Cardiol* 1991; 86: 223-33.
34. Vassalli G, Hess OH, Krogman ON, et al. Coronary artery size in mitral regurgitation and its regression after mitral valve surgery. *Am Heart J* 1993; 126: 1091-8.
35. Motz W, Vogt M, Scheler S, Schwartzkopff B, Stauer BE. Improvement of coronary reserve after regression of hypertrophy resulting from blood pressure reducing treatment with bisoprolol, a beta-receptor blocker. *Dtsche Med Wochenschr* 1993; 118: 535-40.
36. Hartford M, Wendelhag L, Berglund G, Wallentin I, Ljungman S, Wikstrand J. Cardiovascular and renal effects of long-term antihypertensive treatment. *JAMA* 1988; 259: 2553-7.
37. Dunn FG, Ventura HO, Messerli EH, Kobrin I, Frohlich ED. Time course of regression of left ventricular hypertrophy in hypertensive patients treated with atenolol. *Circulation* 1987; 76: 254-8.
38. Ram CV, Gonzalez D, Kulkarni P. Regression of left ventricular hypertrophy in hypertension. Effects of prazosin therapy. *Am J Med* 1989; 86: 66-9.
39. Schmieder RRE, Messerli FH, Garavaglia GE, Nunez BD. Cardiovascular effects of verapamil in patients with essential hypertension. *Circulation* 1987; 75: 1030-6.
40. Grossman E, Oren S, Garavaglia GE, Messerli FH, Frohlich ED. Systemic and regional hemodynamic and humoral effects of nitrendipine in essential hypertension. *Circulation* 1988; 78: 1394-400.
41. Shahi M, Thom S, Poulter N, Sever PS, Foale RA. Regression of hypertensive left ventricular hypertrophy and left ventricular diastolic function. *Lancet* 1990; 336: 458-61.
42. Dunn FG, Oigman W, Ventura HO, Messerli FH, Kobrin I, Frohlich ED. Enalapril improves systemic and renal hemodynamics and allows regression of left ventricular mass in essential hypertension. *Am J Cardiol* 1984; 53: 105-8.
43. Ferrara LA, De Simone G, Mancini M, Fasano ML, Pasanisi F, Vallone G. Changes in left ventricular mass during a double blind study with chlorthalidone and slow release nifedipine. *Eur J Clin Pharmacol* 1984; 27: 525-8.
44. Villari B, Hess OM, Meier C, et al. Regression of coronary artery dimensions after successful aortic valve replacement. *Circulation* 1992; 85: 972-8.
45. Waszyrowski T, Kasprzak JD, Krzeminska-Pakula M, Drozd J, Dziatkowiak A, Zaslanka J. Regression of left ventricular dilatation and hypertrophy after aortic valve replacement. *Int J Cardiol* 1996; 57: 217-25.
46. Parodi O, Neglia D, Palombo C, et al. Comparative effects of enalapril and verapamil on myocardial blood flow in systemic hypertension. *Circulation* 1997; 96: 864-73.