

Robotic-assisted off-pump coronary surgery

Massimo A. Mariani, Alessandro D'Alfonso, Riccardo Codecasa, Jan G. Grandjean

Department of Cardio Thoracic Surgery, University of Pisa, Pisa, Italy

(Ital Heart J 2002; 3 (Suppl 4): 29S-33S)

© 2002 CEPI Srl

Address:

Dr. Massimo A. Mariani

*Dipartimento Cardio
Toracico
Università degli Studi
Ospedale Cisanello
Via Paradisa, 2
56124 Pisa
E-mail:
massimo_mariani@
hotmail.com*

Introduction

Minimally invasive coronary surgery through a small antero-lateral mini-thoracotomy is a safe technique with clear indications and established results^{1,2}. However, the indication is still limited because of the increasing reliability of primary stenting of the left anterior descending coronary artery (LAD). In the conventional approach via a mini-thoracotomy, the harvesting of the left internal mammary artery (LIMA) may result in pain and discomfort because of the spreading of the ribs. Such pain may impair the respiratory movements in the postoperative period. Another problem is represented by the visualization of the intrathoracic structures. Video-assisted thoracoscopy allows the harvesting of the LIMA in a safe way³ without spreading the ribs, therefore significantly reducing the postoperative pain. However, video-assisted thoracoscopy is a rather complicated technique especially for those surgeons who are not confident with thoracoscopic techniques. The recent advances in robotic technology make both LIMA and right internal mammary artery (RIMA) harvesting much easier than the video-assisted thoracoscopy harvesting.

The feasibility of coronary and valve surgery using a robotic-assisted approach has recently been demonstrated⁴⁻¹¹. The future of the coronary surgery might be based on a wider use of robotic technology for an increasing number of patients, with avoidance of both sternotomy and cardiopulmonary bypass. Moreover, new technologies and dedicated instruments for robotic surgery (i.e. endoscopic stabilizer and automatic anastomotic devices) would allow performing off-pump myocardial revascularization through four stab thoracic incisions¹². High costs and peculiar structural

requirements of the operating room limit nowadays the presence of robotic systems into a few centers with high surgical volume (Fig. 1).

This study describes the preliminary results of robotic-assisted coronary surgery in a single university hospital.

Methods

Patients. In our center the da Vinci system (Intuitive SurgicalTM, Mountain View, CA, USA) has been introduced since February 2001. At present 24 patients have successfully undergone LIMA or both mammary artery harvesting. Single LIMA was used for revascularization of the LAD or a diagonal branch and the LAD as a sequential graft, while the RIMA was used as a T-graft for revascularization of the LAD and circumflex coronary arteries. The use of the T-graft of the RIMA to LIMA as a composite graft^{13,14} is a known technique that gives the surgeon length of graft suitable for a long portion of the LAD (in contrast with RIMA-LAD graft) and for the branches of the circumflex coronary artery.

In 2 out of the 24 patients this approach was used for revascularization of the LAD with LIMA and a marginal branch of the circumflex coronary artery with a RIMA T-graft via antero-lateral left mini-thoracotomy. These 2 cases are, by authors' knowledge, the first 2 patients operated on with this previously undescribed technique.

The da Vinci endoscopic system allowed to harvest both the LIMA and RIMA "closed chest", the distal anastomoses being performed through a 6-7 cm thoracotomy by the usual off-pump technique. Preoperative and operative characteristics of all patients are described in tables I and II.

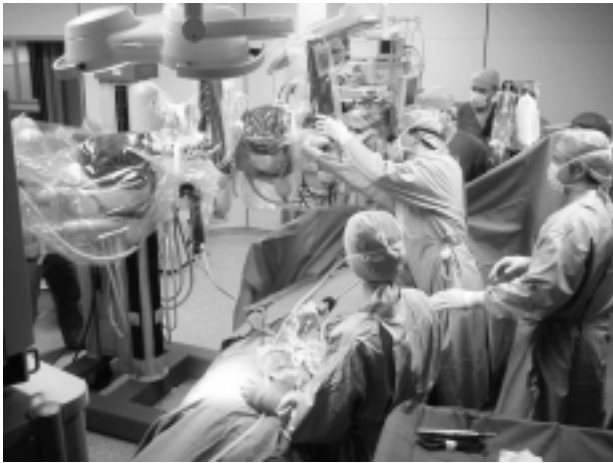

Figure 1. The slave unit approaching the operative table.

Table I. Preoperative characteristics.

Male	21 (88%)
Female	3 (12%)
Age (years)	66 ± 9
Age range (years)	44-87
Body surface area (kg/m ²)	1.8 ± 0.1
Obese patients	2 (8%)
Diabetic patients	4 (16%)
Cerebrovascular disease	1 (4%)
Chronic renal failure	7 (29%)
COPD	2 (8%)
Previous MI	2 (8%)
Previous PTCA	3 (12%)
Hypertension	15 (63%)
Sinus rhythm	24 (100%)
CCS II	12 (50%)
CCS III	10 (42%)
CCS IV	2 (8%)
LVEF (%)	51 ± 8
Parsonnet score	7.5 ± 6.6
EuroSCORE	3.1 ± 2.6
Reoperation	1 (4%)

COPD = chronic obstructive pulmonary disease; LVEF = left ventricular ejection fraction; MI = myocardial infarction; PTCA = percutaneous transluminal coronary angioplasty.

In particular, the 2 patients with both IMAs were male, aged 60 and 55 years respectively. Body mass index and body surface area were 24 kg/m² and 1.81 m² in one patient and 28 kg/m² and 1.86 m² in the other one respectively. Both patients had left main stenosis with a Parsonnet risk score of 3 and 6, respectively. The first patient was urgent for unstable angina, the second patient was diabetic on oral therapy and had peripheral arteriopathy. Both patients were in NYHA functional class II. Left ventricular ejection fraction was 57 and 55% respectively.

Operative technique. Selective double-lumen intubation was used in all procedures. The patient was po-

Table II. Operative characteristics.

No. diseased coronary arteries	44
Average	1.8 ± 0.6
Total graft implanted	27
Emergency	3 (12%)
LIMA to LAD	18 (75%)
LIMA to LAD and diagonal brunch	5 (20%)
LIMA to marginal artery	18 (29%)
T-RIMA to marginal artery	2 (8%)

LAD = left anterior descending coronary artery; LIMA = left internal mammary artery; RIMA = right internal mammary artery.

sitioned supine with the left thorax slightly lifted forming an angle of about 20° with the surgical table. The left arm was positioned laterally, forming an angle of about 75° with the chest and the forearm flexed so that the hand was secured to the table beside at the left hip. Three stab wounds (0.8-1 cm) were made for the ports: one on the third intercostal space in the anterior axillary line, another on the fifth space in the media axillary line, and the last on the seventh space in the anterior axillary line. The stab wound on the fifth space was used for insertion of the 0° (or 30°) optic arm of da Vinci. The other two stab wounds were made for the operative arms (forceps, cauterium, clip applicator) of the system. Once entered the chest, the lung was collapsed and CO₂ inflated in the pleural space to optimize view.

In case of combined RIMA and LIMA harvesting (2 patients) the retrosternal fatty tissue was divided with the cautery to reach the right pleural space: both mammary arteries were harvested by coagulating or clipping the branches, from about the first to the sixth-seventh space. Intravenous heparin 1 mg/kg was given. Since the endoscopic stabilizers are still in the experimental phase and none is currently available on the market, we chose to perform the distal anastomosis through a small thoracotomy. A re-usable custom-made steel coronary stabilizer was used through a small thoracotomy to perform the procedures. The fourth intercostal space was opened by prolonging the stab wound of the optic arm. The RIMA was clipped distally and proximally with a long curve tip clip applicator (Ethicon endo-surgery, Cincinnati, OH, USA), and divided. The LIMA was clipped distally, clamped proximally with a line-secured bulldog (Baxter Healthcare Corporation, Irvine, CA, USA), and divided. Papaverin 1% solution was injected inside the IMAs to induce vasodilation. RIMA was then anastomosed 90° to the LIMA with an 8/0 polypropilene suture creating a T-shaped graft. The pericardium was opened anteriorly to the vagus nerve and suspended with single stitches through the chest wall. The target coronary artery was occluded proximally to the area of anastomosis with a small metallic clamp. All mammary-to-coronary artery anastomoses were performed with an 8/0 polypropilene suture.

Results

Clinical outcomes for all patients are described in table III. Mean hospital stay was 5 ± 3 days. Neither hospital mortality nor low cardiac output, cerebrovascular accident, acute renal failure was observed. In particular the patients with 2 IMAs were discharged 6 and 8 days after the operation respectively, and no postoperative complications were observed.

All 24 patients are alive and doing well at the present time of follow-up.

Table III. Clinical results.

In-hospital death	0
Unit Care stay (hours)	13 ± 8
Mechanical ventilation time (hours)	7 ± 2
Total bleeding (ml)	783 ± 495
Reoperation for bleeding	1 (4%)
Perioperative myocardial infarction	1 (4%)

Discussion

The clinical use of the robotic systems in cardiac surgery has begun in 1998. Preliminary results have a limited scientific significance because of the small number of patients and the strong selection of the patients¹⁵⁻²². The current increasing number of centers involved with a growing number of procedures may foresee the expansion of the robotic technique in the next years. This growth will be certainly influenced by commercial choices from the main producers, based on engineering investments and clinical-economical advantages.

At present there is full agreement about the use of robotic system in various aspects of cardiac surgery. Robotic-assisted cardiac surgery is used for mammary artery harvesting. It is also used for closed-chest coronary bypass grafting of one or two vessels, either on the beating heart or on femoral extracorporeal circulation with the use of the Heartport system¹⁶. Moreover, robotic assistance is used for closed-chest mitral valve repair and atrial septal defect closure on femoral extracorporeal circulation with the use of the Heartport system^{17,21}.

Two robotic systems for cardiac and thoracic surgery are at present available on the market: the da Vinci system and the Zeus system (Computer Motion, Goleta, CA, USA). The Zeus system has the smallest dimensions, is modular, and can be coupled with the operative table¹⁸. The da Vinci system is bigger and not bonded to the operative table.

The peculiarities of the da Vinci system are:

- true three-dimensional vision, thanks to a high-definition binocular optic system with a $10\times$ magnification, that guarantees a better view than the usual video-thoracoscopic view (Fig. 2);



Figure 2. Two-channel endoscope with two cameras (resolution 75% higher than all the other three-dimensional video systems).

- very fine movements of the tip of the endoscopic instruments (Endo-Wrist™, Mountain View, CA, USA) with 6 degrees of freedom, superior to the natural movements of the human hand and wrist. In fact the Endo-Wrist™ system can rotate up to 360° while the human wrist can rotate only up to 180° . The endoscopic arm has a fulcrum of rotation which is immobile at the level of the port for whatever position of the arm. This guarantees an atraumatic behavior for every movement. Although a complete tactile sensitivity is not yet available, the system prevents an excessive strength applied to the intrathoracic organs of the patients by inducing some resistance into the handles (Figs. 3 and 4). Also, the system autoregulates itself in case of collision between the instrumental arms to prevent damage to the system;



Figure 3. Endo-Wrist™ system.



Figure 4. Instrument tip dimensions.

- the three-dimensional optic system is completely steerable through the three dimensions, simply moving the handles of the “master” unit in an intuitive manner. The software of this system always maintains the left-right and the up-down ratio between the optic system and the instrumental arms;
- the ergonomic design of the system reproduces the typical conditions of conventional open-chest surgery, as far as the posture of the surgeon is concerned. In open-chest surgery a straight line can be traced passing through the eyes and the hands of the surgeons towards the operative field. This line cannot be present during conventional video-thoracoscopic procedures because the surgeon must look at a monitor situated away in an appropriate site of the operative room. In the da Vinci system, this “direct” line is guaranteed by the engineering system (Fig. 5).

The system has a control console (“master”), an operative unit (“slave”) and a video-unit (“tower”) for the operative room équipe. The “master” unit contains two handles and four pedals for a complete control of the instruments, the definition of the view and the focusing and the use of the electrocautery device. The software of the machine filters the random movements of the hand so that the tremor is eliminated, with a very accurate grade of surgical performing. In addition, this accuracy can be modulated by increasing the ratio of demultiplication between the movements of the surgeon and those of the endoscopic instruments. The surgeon sits at the master console to perform the procedure. The

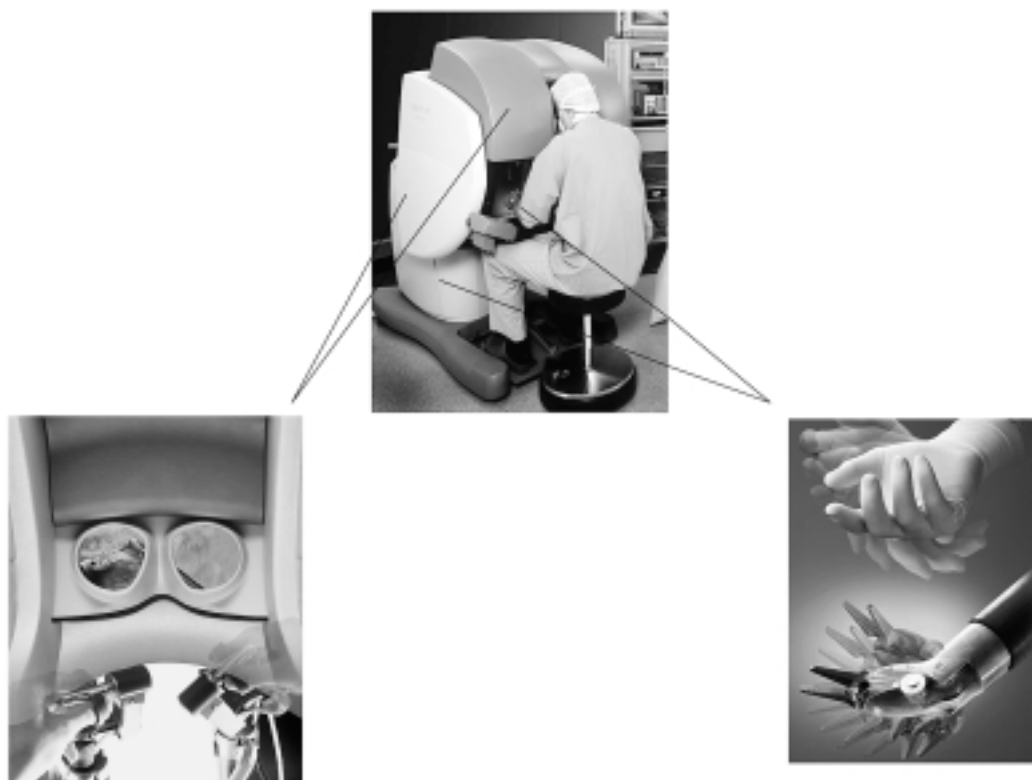


Figure 5. Head-hands-operative field line in the da Vinci system.

master unit “recognizes” the presence of the surgeon by sensing the presence of his head when he is watching through the viewer and it activates the instruments at that time. The master console can be placed close to the operative table (as usual) or in another appropriate room. This could provide the background for the so-called “telesurgery” (operator from a remote site).

In conclusion, the usefulness of the robotic system consists in “bringing” the hands and the eyes of the surgeon inside the body without breaking its integrity with a large surgical wound. The advantages are obviously not only cosmetic; the absence of a conventional surgical access primarily implies the avoidance of the wound-related complications (dehiscence or infection) and secondarily allows a fast recovery of the patient.

The combination of the conventional T-graft off-pump revascularization with robot-assisted LIMA-RIMA harvesting is an interesting technique for revascularization of the left heart especially in patients with diabetes and/or chronic obstructive pulmonary disease in order to prevent sternotomy-related complications. It could be an intermediate phase towards a complete closed chest left myocardial revascularization.

Although the future of robotic surgery is not easily predictable, the general trend of surgery is moving towards the minimization of the surgical trauma thanks to a wide use of video-assisted systems^{23,24}. The diffusion of robotic systems on a large scale might cause a decrease of the costs of the systems resulting in a reduction of social costs as well as early return to normal life, through a short hospital stay and a fast recovery.

References

1. Calafiore AM, Giammarco GD, Teodori G, et al. Left anterior descending coronary artery grafting via left anterior small thoracotomy without cardiopulmonary bypass. *Ann Thorac Surg* 1996; 61: 1658-65.
2. Cremer J, Struber M, Wittwer T, et al. Off-bypass coronary bypass grafting via minithoracotomy using mechanical epicardial stabilization. *Ann Thorac Surg* 1997; 63 (Suppl): S79-S83.
3. Martinelli GL, Cassese M, Speziali G, et al. Myocardial revascularization through a mini-thoracotomy with thoracoscopic assistance. *Eur J Cardiothorac Surg* 1998; 14 (Suppl 1): S68-S70.
4. Gulielmos V, Knaut M, Cichon R, et al. Minimally invasive surgical treatment of coronary artery multivessel disease. *Ann Thorac Surg* 1998; 66: 1018-21.
5. Gulielmos V, Brandt M, Knaut M, et al. The Dresden approach for complete multivessel revascularization. *Ann Thorac Surg* 1999; 68: 1502-5.
6. Reichenspurner H, Gulielmos V, Daniel WG, Schuler S. Minimally coronary-artery bypass surgery. *N Engl J Med* 1997; 336: 67-8.
7. Loulmet D, Carpentier A, d'Attellis N, et al. Endoscopic coronary artery bypass grafting with the aid of robotic assisted instruments. *J Thorac Cardiovasc Surg* 1999; 118: 4-10.
8. Falk V, Diegeler A, Walther T, et al. Total endoscopic computer enhanced coronary artery bypass grafting. *Eur J Cardiothorac Surg* 2000; 17: 38-45.
9. Kappert U, Cichon R, Schneider J, Schram I, Schuler S. Closed chest bilateral mammary artery grafting in double-vessel coronary artery disease. *Ann Thorac Surg* 2000; 70: 1699-701.
10. Damiano RJ Jr, Ehrman WJ, Ducko CT, et al. Initial United States clinical trial of robotically assisted endoscopic coronary artery bypass grafting. *J Thorac Cardiovasc Surg* 2000; 119: 77-82.
11. Kappert U, Cichon R, Schneider J, et al. Closed chest coronary artery surgery on the beating heart using a robotic system. *J Thorac Cardiovasc Surg* 2000; 120: 809-11.
12. Nakamura Y, Kishi K. Robotic stabilization that assists cardiac surgery on beating hearts. *Stud Health Technol Inform* 2001; 81: 355-61.
13. Bonacchi M, Prifti E, Frati G, et al. Total arterial myocardial revascularization using new composite graft techniques for internal mammary and/or radial arteries conduits. *J Card Surg* 1999; 14: 408-16.
14. Calafiore AM, Di Giammarco G, Luciani N, Maddestra N, Di Nardo E, Angelini R. Composite arterial conduits for a wider arterial myocardial revascularization. *Ann Thorac Surg* 1994; 58: 185-90.
15. Mack MJ. Coronary surgery: off-pump and port access. *Surg Clin North Am* 2000; 80: 1575-91.
16. Mohr FW, Falk V, Diegeler A, et al. Computer-enhanced “robotic” cardiac surgery: experience in 148 patients. *J Thorac Cardiovasc Surg* 2001; 121: 842-53.
17. Vanermen H, Wellens F, De Geest R, Degrieck I, Van Praet F. Video-assisted Port-Access mitral valve surgery: from debut to routine surgery. Will Trocar-Port-Access cardiac surgery ultimately lead to robotic cardiac surgery? *Semin Thorac Cardiovasc Surg* 1999; 11: 223-34.
18. Gulbins H, Boehm DH, Reichenspurner H, Arnold M, Ellgass R, Reichart B. 3D-visualization improves the dry-lab coronary anastomoses using the Zeus robotic system. *Heart Surg Forum* 1999; 2: 318-25.
19. Kappert U, Schneider J, Cichon R, et al. Closed chest totally endoscopic coronary artery bypass surgery: fantasy or reality? *Curr Cardiol Rep* 2000; 2: 558-63.
20. Prasad SM, Ducko CT, Stephenson ER, Chambers CE, Damiano RJ Jr. Prospective clinical trial of robotically assisted endoscopic coronary grafting with 1-year follow-up. *Ann Surg* 2001; 233: 725-32.
21. Torracca L, Ismeno G, Alfieri O. Totally endoscopic atrial septal defect closure using robotic techniques: report of two cases. *Ital Heart J* 2002; 1: 698-701.
22. Cichon R, Kappert U, Schneider J, et al. Robotically enhanced “Dresden technique” with bilateral internal mammary artery grafting. *Thorac Cardiovasc Surg* 2000; 48: 189-92.
23. Kappert U, Cichon R, Schneider J, et al. Robotic coronary artery surgery - the evolution of a new minimally invasive approach in coronary artery surgery. *Thorac Cardiovasc Surg* 2000; 48: 193-7.
24. Rotnes JS, Kaasa J, Westgaard G, et al. Digital trainer developed for robotic assisted cardiac surgery. *Stud Health Technol Inform* 2001; 81: 424-30.