

Modern strategies to prevent coronary restenosis

Alaide Chieffo, Goran Stankovic, Antonio Colombo

Laboratory of Interventional Cardiology, EMO Centro Cuore Columbus, and Fondazione Centro San Raffaele del Monte Tabor, Milan, Italy

(Ital Heart J 2002; 3 (Suppl 4): 9S-15S)

© 2002 CEPI Srl

Address:

Dr. Antonio Colombo

Laboratorio di Cardiologia
Interventistica
EMO Centro
Cuore Columbus
Via M. Buonarroti, 48
20145 Milano
E-mail: columbus@
micronet.it

The first strategy that was shown effective to lower restenosis following balloon angioplasty has been stent implantation. The level of evidence for this finding is quite high and comes from three major randomized trials: the BENESTENT I trial (Belgian-Netherlands Stent Study I)^{1,2}, the BENESTENT II study³, and the STRESS trial (Stent Restenosis Study)⁴.

The second level of evidence is that optimization of stent implantation, using intravascular ultrasound (IVUS) guidance in order to maximize final lumen diameter, gives a better outcome on long term. The level of evidence for this approach is nevertheless lower and is not fully supported by randomized trials but mainly by observational studies, and moreover there are some discordant data coming from the randomized trials⁵⁻⁹. However, unless there is a wide separation in procedural gain between the angiographic guidance group and the IVUS guidance group we cannot expect an impact on restenosis.

The third approach that can be used to reduce restenosis rate is directional atherectomy (DCA) with lesion debulking prior to stenting. The level of evidence for this approach comes only from Registries. The three Registries, which give concordant positive results, are the SOLD Registry (Stenting after optimal lesion debulking Registry)¹⁰, the Registry from Bramucci et al.¹¹, and the AtheroLink Registry¹².

The results of the recently completed AMIGO trial (Atherectomy before Multilink Improves lumen Gain and clinical Outcome) has not yet been presented. Only two Centers' experience (Columbus Hospital and San Raffaele Hospital from Milan) is available at the moment and reported a benefit of DCA and stenting vs stenting alone¹³.

Among the non-mechanical approaches to prevent and to treat restenosis we would like to mention the usage of intracoronary radiation therapy, which had proven its efficacy in several randomized trials¹⁴⁻¹⁷.

Finally, for tomorrow, we have the limited evidence based on the usage of drug-eluting stents. This evidence is so far supported by the recently reported RAVEL study (RANdomized, double-blind study with the sirolimus-eluting BX VELOCITY balloon expandable stent in the treatment of patients with *de novo* native coronary artery Lesions)¹⁸, but we are eagerly waiting long-term results and the results of several other ongoing trials.

The BENESTENT I trial was the first trial which clearly showed that stenting is superior to angioplasty¹. The positive impact on restenosis is manifested by a 10% absolute lower incidence of restenosis rate by the 50% angiographic criteria in the stent group vs angioplasty group (22 and 32%, respectively, $p = 0.02$). The main problem of this trial was the high incidence of bleeding and vascular complications which were more frequent after stenting than after balloon angioplasty (13.5 vs 3.1%, $p < 0.001$) and were related to the strong anticoagulant therapy these patients were subjected. Similar results were obtained in the STRESS trial⁴ in which the placement of an intracoronary stent, as compared with balloon angioplasty, resulted in a lower angiographic restenosis rate after 6 months (31.6 vs 42.1%, $p = 0.046$) and a less frequent need for target lesion revascularization (TLR) (10.2 vs 15.4%, $p = 0.06$). The multicenter, randomized BENESTENT II study investigated a strategy of implantation of a heparin-coated Palmaz-Schatz stent compared with the use of balloon angioplasty alone,

and showed a further reduction of restenosis of 16 vs 31% ($p = 0.0008$)³. However, over a 12-month follow-up, a strategy of elective stenting with heparin-coated stents was more effective but also more costly than conventional balloon angioplasty.

The goal to obtain the largest luminal diameter during the procedure is now the primary goal of all angioplasty procedures and is one of the major explanations why stents reduce restenosis and why their use has become so popular. Often termed "bigger is better", that inverse relationship between final minimal lumen diameter (MLD) or percent residual stenosis and occurrence of restenosis has been widely studied and well validated¹⁹. One approach to optimize the results is to use IVUS guidance. However results from randomized trials evaluating that approach are discordant. Several criteria for optimal stent implantation have been proposed and used in clinical studies (Table I)^{5,6,20}. In the CRUISE study (Can Routine Ultrasound Influence Stent Expansion study), a total of 525 patients were enrolled comparing angiographic vs IVUS guidance, and clinical outcome at 9 months⁷. The primary endpoint of this study was the postprocedure minimal stent dimensions as assessed by angiography and IVUS, and the secondary endpoint was the incidence of major adverse cardiac events and target vessel revascularization (TVR) at 9 months. The IVUS-guided group had a larger MLD (2.9 ± 0.4 vs 2.7 ± 0.5 mm, $p < 0.001$) by quantitative coronary angiography and a larger minimal stent area (7.78 ± 1.72 vs 7.06 ± 2.13 mm, $p < 0.001$) by quantitative coronary ultrasound. The rate

of TVR was significantly lower in the IVUS-guided group (8.5 vs 15.3%, $p < 0.05$; relative reduction of 44%). Similar findings were reported in the TULIP study (Thrombocyte activity evaluation in the study to determine the effect of Ultrasound guidance of Long Intracoronary stent Placement)⁸. In that study 150 patients with coronary stenosis > 20 mm were randomized to IVUS or no-IVUS-guided stent implantation. Despite the use of more stents as well as longer stents, the 6-month angiographic and clinical outcomes in the IVUS-guided group were superior to angiographic group. The acute gain was significantly higher in the IVUS group (2.0 vs 1.8 mm in the angiographic group, $p = 0.04$), resulting in lower restenosis rate (20 vs 36%, $p = 0.05$). Total major adverse cardiac events were also significantly lower in the IVUS group (12 vs 30%, $p = 0.045$), this effect was due primarily to a lower TLR rate (6 vs 16%, $p = 0.045$). These data suggested that IVUS guidance of stent implantation may result in more effective stent expansion compared with angiographic guidance alone. On the other hand, in the OPTICUS trial (OPTimization with ICUS to reduce stent restenosis)⁹ at 6 months, repeat angiography revealed no significant differences between the groups with ultrasound- or angiography-guided stent implantation with respect to dichotomous restenosis rate (24.5 vs 22.8%, $p = 0.68$), MLD (1.95 ± 0.72 vs 1.91 ± 0.68 mm, $p = 0.52$), and percent diameter stenosis (34.8 ± 20.6 vs 36.8 ± 19.6 %, $p = 0.29$), respectively. These data were explained by the authors as a consequence of the remarkable good acute angiographic results in the angiography-guided group, which were close to those achieved in the IVUS-guided group; MLD was 3.02 ± 0.49 mm in the IVUS-guided group vs 2.91 ± 0.41 mm ($p = 0.006$), and acute lumen gain was 2.07 ± 0.50 vs 1.91 ± 0.66 mm ($p < 0.0001$). Similarly, in the RESIST trial (REStenosis after Ivus guided STenting)⁶ at 6 months there was no significant difference in the restenosis rate in the IVUS-guided group compared to the angiography-guided group (22.5 vs 28.8%, $p = 0.25$), as well as in the MLD (1.70 ± 0.64 vs 1.60 ± 0.65 mm, $p = 0.20$).

The concept of lumen optimization with maximal stent expansion may not apply in small vessels (< 2.8 mm) in which trauma from excessive lumen dilation may impact a severe intimal proliferation which is not counteracted by the residual small lumen^{21,22}. In this setting a more conservative strategy may be of advantage^{23,24}.

Another promising approach to obtain maximal postprocedural MLD is atherosclerotic plaque removal with DCA before stent implantation. The support towards this approach comes from the observation that the plaque burden is an important determinant for restenosis²⁵. Encouraging data were published from the SOLD Registry, which reported a 6-month angiographic restenosis rate of 11% (95% confidence interval 5 to 20%) and a TLR rate of 7% (95% confidence interval 3

Table I. Intravascular ultrasound criteria for optimal stent expansion.

*The MUSIC study criteria*⁵

1. Complete apposition of the stent over its entire length.
2. Symmetric stent expansion defined by (minimal lumen diameter/maximal lumen diameter) ≥ 0.7 .
3. In-stent minimal lumen area $\geq 90\%$ of the average reference lumen area or 100% of lumen area of the reference segment with the lowest lumen area. In-stent lumen area of the proximal stent entrance $\geq 90\%$ of proximal reference lumen area. In case the in-stent lumen area > 9.0 mm²: in-stent minimal lumen area $\geq 80\%$ of the average reference lumen area or $\geq 90\%$ of lumen area of the reference segment with the lowest lumen area. In-stent lumen area of proximal stent entrance $\geq 90\%$ of proximal reference lumen area.

*Colombo et al. criteria*²⁰

1. Good stent apposition to the vessel wall with good plaque compression.
2. 60% of the average of the proximal and distal cross sectional area or in-stent minimal lumen cross-sectional area \geq distal reference cross-sectional area.
3. Area stenosis immediately adjacent to the stent (proximal and distal) $> 60\%$ relative to the adjacent reference lumen.

*The RESIST study criteria*⁶

1. The ratio of intrastent cross-sectional area to the average of the proximal and distal reference lumen cross-sectional area with a cut-off point at 80%.

to 14%) in patients treated with debulking before stent implantation¹⁰. Similar results were reported by Bramucci et al.¹¹, who presented a 6.8% restenosis rate in 94 patients treated with DCA prior to stenting compared to a 30.5% in a matched group of 94 patients treated with stent implantation alone ($p < 0.0001$). In the same study a higher incidence of major adverse cardiac events in patients treated with stent alone was also reported (27 vs 15%, $p < 0.0001$) at 6-month follow-up.

The first randomized trial, the AMIGO trial, has been completed with an enrollment of 753 patients from 56 sites in Europe and the United States to test the hypothesis of debulking prior to stenting supported by findings of those two Registries. The complete results of this trial are not yet available. Two centers (Columbus Hospital and San Raffaele Hospital in Milan) enrolled a total of 97 patients with 107 lesions (60 patients enrolled in the Columbus Hospital and 37 patients in the San Raffaele Hospital). The results of these two Centers analyzed on site shows a strong trend for a lower restenosis (15 vs 33%, $p = 0.07$) when DCA precedes stenting¹³. The results of the DESIRE trial (Debulking and Stenting In Restenosis Elimination) have recently been reported at the last meeting of the American Heart Association. In this study 500 patients with *de novo* coronary lesions were randomized to DCA and stenting vs stenting alone. Despite a larger acute lumen gain measured by IVUS in the DCA and stenting group vs the stenting group, there was only a numerically lower restenosis rate at follow-up inside the stent (10.4 vs 15.1% respectively, $p = 0.16$) with a similar restenosis rate in the lesion (15.3 vs 16.1%) and a similar TVR (12.9 vs 12.2%)²⁶. The neg-

ative results of the DESIRE trial are probably due to the selection of lesions with a very low risk of restenosis following simple stenting. The major limitation to perform DCA on a routine basis, especially in complex lesions where this strategy is likely to be more effective relates to the fact that no very friendly device to debulk the lesion is currently available. The possibility of seeing the emergence of a new more friendly and effective debulking device is the only hope to revitalize this area (Fig. 1).

Among the non-mechanical approaches to prevent and to treat restenosis we would like to mention the usage of intracoronary radiation therapy. Three major trials, the SCRIPPS trial (Scripps Coronary Radiation to Inhibit Proliferation Post-Stenting)¹⁴, the WRIST trial (Washington Radiation for In-Stent restenosis)¹⁵ and the GAMMA-One trial (Localized intracoronary gamma-radiation therapy to inhibit the recurrence of restenosis after stenting)¹⁶ have all confirmed that this approach is effective in treating in-stent restenosis. All these trials use the gamma-radiation that has a stronger penetration capacity but requires also a dedicated protection system in the catheterization laboratory. In the SCRIPPS trial 55 patients were enrolled and randomized to the iridium-192 group or to the placebo group; angiographic restenosis occurred in 17% of the patients in the iridium-192 group, as compared with 54% of those in the placebo group ($p = 0.01$)¹⁴. In the WRIST trial 130 patients with in-stent restenosis were randomized to receive either intracoronary gamma-radiation with iridium-192 (15 Gy) or placebo¹⁵. At 6 months, patients assigned to radiation therapy required less TLR and TVR (13.8 and 26.2%, respectively) com-

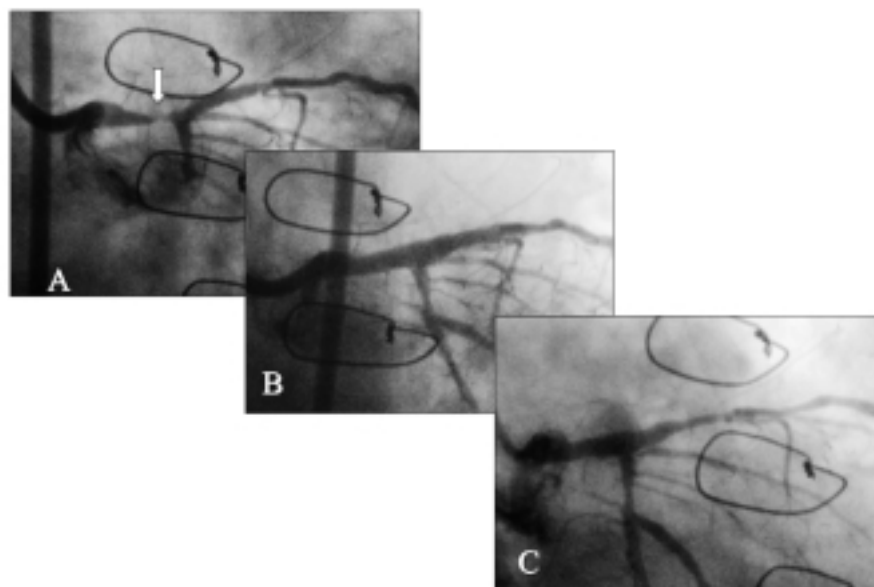


Figure 1. A: baseline angiogram of a 62-year-old male who presented with stable angina 8 years following coronary artery bypass graft with an occluded left internal mammary artery graft to the left anterior descending coronary artery; notice the severe stenosis of the distal left main coronary artery. B: final angiogram after coronary atherectomy and stent implantation in the distal left main coronary artery. C: 8-month follow-up angiogram showing the minimal lumen loss in the treated segment.

pared with patients assigned to placebo (63.1 and 67.7%, respectively, $p = 0.0001$). Binary angiographic restenosis was lower in the irradiated group (19 vs 58% for placebo, $p = 0.001$).

In the GAMMA-One trial 252 eligible patients with in-stent restenosis were randomly assigned to receive an intracoronary brachytherapy using iridium-192 or placebo¹⁶. The primary endpoint, a composite of death, myocardial infarction, and the need for repeated revascularization of the target lesion during 9 months of follow-up, occurred in 43.8% of patients assigned to placebo vs 28.2% of patients assigned to iridium-192 ($p = 0.02$). However, the reduction in the incidence of major adverse cardiac events was determined solely by a diminished need for TLR, not by reductions in the incidence of death or myocardial infarction. In this trial a particular positive effect of radiation therapy has been shown in diabetic patients in whom the restenosis rate reduction occurred in the 52% of the patients compared to 33% in patients without diabetes.

Similar positive results have also been obtained by utilizing intracoronary beta-radiation for treatment of in-stent restenosis in the START trial (Stents and Radiation Therapy)²⁷. In this study 232 patients were randomized to placebo while 244 patients were randomized to strontium-90 using the Novoste Beta-Cath System (Novoste, Norcross, GA, USA). Overall, 31% reduction of major adverse cardiac events and 34% reduction in TVR were found.

At present, except for one randomized study, very few reports are addressing usage of brachytherapy in primary prevention of restenosis¹⁷. In that dose-finding study, 181 patients were randomly assigned to receive 9, 12, 15, or 18 Gy of beta-radiation, delivered by a centered yttrium-90 source following successful balloon angioplasty of *de novo* coronary lesions. At the time of follow-up coronary angiography, the mean MLD was 1.67 mm in the 9-Gy group, 1.76 mm in the 12-Gy group, 1.83 mm in the 15-Gy group, and 1.97 mm in the 18-Gy group ($p = 0.06$ for the comparison of 9 with 18 Gy), resulting in restenosis rates of 29, 21, 16, and 15%, respectively ($p = 0.14$ for the comparison of 9 with 18 Gy).

Main limitations of brachytherapy are the occurrence of "edge effect"^{28,29} and late coronary thrombosis³⁰. The "edge effect" represents the development of new stenosis at the edges of the irradiated segment and is explained by the combination of injury and low-dose radiation. Therefore the term "geographic miss" is introduced to define cases in which the radiation source did not fully cover the injured area. A higher late loss rate as well as a higher restenosis rate were reported in geographic miss edges compared to segments who received full radiation dose in injured and uninjured edges²⁸.

Another major limitation related to brachytherapy is late coronary thrombosis especially when new stents are implanted. Waksman et al.³⁰ reviewed the records of 473 patients with in-stent restenosis who

were enrolled in various radiation protocols or entered into Registries. Maximum dose to the vessel wall was 30 to 55 Gy. Following radiation all patients received antiplatelet therapy with aspirin and either ticlopidine or clopidogrel for 1 month. All patients completed at least 6 months of clinical and had angiographic follow-up. Late total occlusions were documented in 9.1% of patients from the irradiated group vs 1.2% in placebo group ($p < 0.0001$). The late total occlusion rates were similar across studies and different types of radiation used. The two most important factors associated with an increased risk of late total occlusions were a short duration of combined antiplatelet therapy and a high rate of re-stenting (for the entire study group re-stenting was performed in 48.6% of the lesions at the time of radiation delivery). Importantly, new stents were placed in 82% of the irradiated and in 100% of the placebo patients who presented with late total occlusions. Multivariate analysis determined that new stenting was the main predictor of late total occlusions. Benefit of prolonged (6 months) combined antiplatelet therapy was confirmed in the WRIST-PLUS study³¹ showing rates of total occlusion and late thrombosis 5.8 and 2.5%, respectively. Those rates were lower than the ones in the active gamma-radiation group and similar to those in the placebo historical control group.

The most promising strategy to prevent new intima proliferation and to reduce restenosis has been to coat the stent with an active antiproliferative drug. Among them the early works involved the usage of taxol or derivatives of taxol and rapamycin.

Paclitaxel (Taxol) is a microtubule-stabilizing agent with potent antiproliferative activity. Unlike other antimitotic agents of the colchicine type, it shifts the microtubule equilibrium towards assembly, leading to reduced proliferation, migration and signal transduction³². Paclitaxel has been demonstrated to inhibit smooth muscle cell proliferation and migration in a dose-dependent manner *in vitro* and to prevent neointima formation after balloon angioplasty^{33,34} and after stenting³⁵ in animal models. The long-lasting effect after just several minutes of exposure makes this lipophilic substance a promising candidate for local antiproliferative therapy of restenosis. The first clinical experience has been performed with a taxane analogue (Qp2) embedding plastic sleeves mounted on a stent and showed at 6 months minimal amount of neointimal proliferation in the stented segment³⁶. Late lumen loss at the reference sites adjacent to the stent was acceptable and predominantly due to plaque proliferation. The first randomized trial to evaluate the use of Qp2 coated stent (Quadds-Qp2, Quanam, Santa Clara, CA, USA) vs bare stent (Quest) in the prevention of restenosis has been the SCORE trial (Study to COMPare REstenosis rate between Quest and Quadds-Qp2)³⁷. At 30 days in the coated stent group the incidence of major adverse cardiac events was 10.2%, periprocedural

infarction occurred in 7.1% of the patients, and a 5.5% rate of subacute stent thrombosis was reported. The high incidence of events in the coated stent group was partly a consequence of the coverage of side branches due to the polymer sleeve and to the high subacute thrombosis. Nevertheless, at 6-month angiographic follow-up the Quadds-Qp2 achieved 60% relative reduction in late lumen loss (1.2 vs 3.0 mm of the non-coated group) (Fig. 2).

Animal studies^{33,34} showed efficient endothelization with blockage of intimal hyperplasia when stents were coated with the low dose of paclitaxel (1-4 $\mu\text{g}/\text{mm}^2$). However, histological findings suggested incomplete healing in the higher-dose (42.0 and 20.2 μg of paclitaxel per stent) paclitaxel-containing stents consisting of persistent intimal fibrin deposition, inraintimal hemorrhage, and increased intimal and adventitial inflammation³⁸.

The new drug-eluting stent from Boston Scientific (Boston, MA, USA) utilizing low dosages of paclitaxel (1 $\mu\text{g}/\text{mm}^2$) seems therefore a promising approach to reduce restenosis while preserving stent endothelization. Recently the very promising preliminary results of the TAXUS I trial were presented³⁹. The TAXUS I trial is a randomized trial which evaluated the safety and performance of slow-release paclitaxel eluting NIRx vs non-coated NIR stent. At 6-month follow-up the major adverse cardiac event rate was 0% in the coated group vs 7% in the control group, and events consisted solely of TVR. Six-month angiographic follow-up in NIRx group revealed a reduction of 57% in late lumen loss (0.35 ± 0.47 vs 0.71 ± 0.48 mm, $p = 0.0062$) and a 60% reduction in late loss index (0.20 ± 0.25 vs 0.46 ± 0.29 , $p = 0.0009$). Moreover, the binary restenosis rate was 0% in the NIRx vs 11% in the control group.

Using the same drug for stent coating, encouraging preliminary data come from another two randomized trials, the ASPECT trial (Asian paclitaxel-coated stent clinical trial)⁴⁰ and the ELUTES trial (Evaluation of paclitaxel eluting stent)⁴¹. The ASPECT trial is a ran-

domized, triple-blind design study which evaluated the safety and efficacy of Supra Gtm stent (Cook, Broomfield, CO, USA) coated with paclitaxel (no polymer) at the dosage of 3.1 $\mu\text{g}/\text{mm}^2$ (high dose) and at 1.3 $\mu\text{g}/\text{mm}^2$ (low dose) in the prevention of restenosis⁴⁰. At 6 months the binary restenosis rate was reduced from 27% in the control group to 4% in the high-dose paclitaxel group.

Similar results were reported from the ELUTES trial, in which V-Flex Plus stent (Cook, Broomfield, CO, USA) coated with paclitaxel (no polymer) was evaluated⁴¹. The patients were randomized into five treatment arms: control stent (no paclitaxel), low-dose density (0.2 $\mu\text{g}/\text{mm}^2$), medium-low dose density (0.7 $\mu\text{g}/\text{mm}^2$), medium-high dose density (1.4 $\mu\text{g}/\text{mm}^2$), high dose density (2.7 $\mu\text{g}/\text{mm}^2$). At 6-month angiographic follow-up the binary restenosis was 3% in the high-dose paclitaxel eluting stent group vs 21% in the control group.

The most rewarding result has been so far reported with a stent coated with rapamycin. Rapamycin (sirolimus) has been demonstrated to inhibit smooth muscle cell proliferation and migration *in vitro* and to reduce neointima formation in animal models of vascular injury⁴²⁻⁴⁵.

Rapamycin, binding the cytosolic receptor FKBP12, upregulates p27 levels and inhibits the phosphorylation of retinoblastoma protein (pRb) by blocking the cell cycle progression at the G1-S transition⁴⁶.

Sousa et al.⁴⁷ recently reported a registry (FIM, First In Men) of 45 patients with *de novo* coronary disease treated with two different formulations of sirolimus-eluting BX velocity stent (Cordis, a Johnson & Johnson Company, Warren, NJ, USA) (fast release in group 1 and slow release in groups 2 and 3). None of the patients approached $\geq 50\%$ diameter stenosis at 1 year by angiography or IVUS assessment, and no edge restenosis was observed. Neointimal hyperplasia, as detected by IVUS, was virtually absent at 6 and 12 months. These results are supported by the recently reported

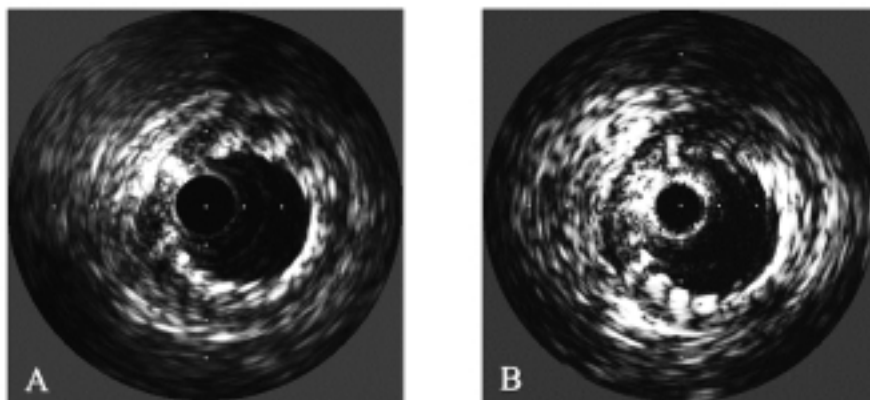


Figure 2. A: intravascular ultrasound exam performed after the implantation of the Quadds Qp2 stent (Quanam, Santa Clara, CA, USA) (a stent partially covered with a polymeric sleeve carrying a taxol derivative). B: intravascular ultrasound exam repeated 6 months from the implantation shows a remarkable absence of intimal hyperplasia.

RAVEL trial¹⁸, which showed at 6 months a restenosis rate of 0% in the patients treated with sirolimus-eluting stent vs 26% in patients receiving a non-coated stent. Moreover, the late lumen loss in the drug-eluting stent group was -0.01 mm. No subacute thrombosis occurred and the event-free survival rate was 97% in the sirolimus-eluting stent group. Ongoing multicenter randomized study, the SIRIUS trial (SIRoIImUS-coated BX Velocity™ balloon-expandable stent in the treatment of patients with *de novo* coronary artery lesions)⁴⁸ evaluates efficacy in higher risk lesions (2.5-3.5 mm in diameter and 15-30 mm in length). At 1 month clinical follow-up the major adverse clinical event rate was similar in the two groups (5.0 vs. 5.3%) without acute or subacute thrombosis in each group.

The E-SIRIUS study (A European multicenter, randomized, double-blind study of the SIRoIImUS-coated BX velocity balloon expandable stent in the treatment of patients with *de novo* coronary artery lesions, (<http://www.tctmd.com/expert-presentations/table-2.html?product-id=14796&sort-key=336ppt-slide-id=10258>) which is ongoing in Europe evaluates this stent on lesions located in vessels with a reference size of 2.5-3.0 mm and with a lesion length of 15-32 mm.

Despite these very positive results we should maintain our skepticism. The data are preliminary, the number of patients studied small, the lesions on which we have complete follow-up so far, are not complex and the follow-up period still too short for a final word. An issue of toxicity may emerge, either from the medication itself or the polymer delivery vehicle. Preclinical studies reported adverse reactions like intimal hemorrhage, incomplete healing, intimal fibrin deposition, adventitial inflammation and medial necrosis that could translate into clinical complications. Furthermore, looking critically at the MLD changes over the 12-month follow-up period in the registry of Sousa et al.⁴⁷, MLD loss in the fast group had "caught up" to and surpassed that of slow release group. Maybe, over a longer follow-up period an even slower releasing stent would maintain a larger lumen. Current plans for 18-24-month angiographic follow-up in the first group of sirolimus-stented patients will provide important long-term surveillance data⁴⁹. Another area of concern is the negative loss with a mean value < 0. This means that there are a number of lesions with expansion and therefore stent to lumen separation (20% in the RAVEL study). Before dismissing this finding as a clinically irrelevant IVUS observation we need a larger group of patients with a longer follow-up.

Conclusions

At the present time the best known approach to restenosis reduction is to improve the final result and, at least in some lesion subsets, to remove the plaque prior to stenting when the anatomy allows to do so.

The future looks very promising due to the introduction of drug-eluting stents. If this preliminary results will be confirmed a major change in interventional cardiology will take place.

References

1. Serruys PW, de Jaegere P, Kiemeneij F, et al. A comparison of balloon-expandable-stent implantation with balloon angioplasty in patients with coronary artery disease. BENESTENT Study Group. *N Engl J Med* 1994; 331: 489-95.
2. Macaya C, Serruys PW, Ruygrok P, et al. Continued benefit of coronary stenting versus balloon angioplasty: one-year clinical follow-up of BENESTENT trial. BENESTENT Study Group. *J Am Coll Cardiol* 1996; 27: 255-61.
3. Serruys PW, van Hout B, Bonnier H, et al. Randomised comparison of implantation of heparincoated stents with balloon angioplasty in selected patients with coronary artery disease (BENESTENT II). *Lancet* 1998; 352: 673-81.
4. Fischman DL, Leon MB, Baim DS, et al. A randomized comparison of coronary-stent placement and balloon angioplasty in the treatment of coronary artery disease. Stent Restenosis Study Investigators. *N Engl J Med* 1994; 331: 496-501.
5. de Jaegere P, Mudra H, Figulla H, et al. Intravascular ultrasound-guided optimized stent deployment. Immediate and 6 month clinical and angiographic results from the Multicenter Ultrasound Stenting in Coronaries Study (MUSIC Study). *Eur Heart J* 1998; 19: 1214-23.
6. Schiele F, Meneveau N, Vuilleminot A, et al. Impact of intravascular ultrasound guidance in stent deployment on 6-month restenosis rate: a multicenter, randomized study comparing two strategies - with and without intravascular ultrasound guidance. RESIST Study Group. *REStenosis after Ivus guided STenting*. *J Am Coll Cardiol* 1998; 32: 320-8.
7. Fitzgerald PJ, Oshima A, Hayase M, et al. Final results of the Can Routine Ultrasound Influence Stent Expansion (CRUISE) study. *Circulation* 2000; 102: 523-30.
8. Di Marco J. Results from late-breaking clinical trials sessions at ACC 2001. *J Am Coll Cardiol* 2001; 38: 595-612.
9. Mudra H, di Mario C, de Jaegere P, et al. Randomized comparison of coronary stent implantation under ultrasound or angiographic guidance to reduce stent restenosis (OPTICUS Study). *Circulation* 2001; 104: 1343-9.
10. Moussa I, Moses J, Di Mario C, et al. Stenting after optimal lesion debulking (SOLD) registry. Angiographic and clinical outcome. *Circulation* 1998; 98: 1604-9.
11. Bramucci E, Angoli L, Merlini PA, et al. Adjunctive stent implantation following directional coronary atherectomy in patients with coronary artery disease. *J Am Coll Cardiol* 1998; 32: 1855-60.
12. Hopp HW, Baer FM, Ozbek C, Kuck KH, Scheller B. A synergistic approach to optimal stenting: directional coronary atherectomy prior to coronary artery stent implantation - the AtheroLink Registry. AtheroLink Study Group. *J Am Coll Cardiol* 2000; 36: 1853-9.
13. Takagi T, Colombo A, Nishida T, et al. A randomized study of directional atherectomy prior stenting versus stenting alone: a single site experience. (abstr) *Eur Heart J* 2001; 22: 684.
14. Teirstein PS, Massullo V, Jani S, et al. Catheter-based radiotherapy to inhibit restenosis after coronary stenting. *N Engl J Med* 1997; 336: 1697-703.

15. Waksman R, White RL, Chan RC, et al. Intracoronary gamma-radiation therapy after angioplasty inhibits recurrence in patients with in-stent restenosis. *Circulation* 2000; 101: 2165-71.
16. Leon MB, Teirstein PS, Moses JW, et al. Localized intracoronary gamma-radiation therapy to inhibit the recurrence of restenosis after stenting. *N Engl J Med* 2001; 344: 250-6.
17. Verin V, Popowski Y, de Bruyne B, et al. Endoluminal beta-radiation therapy for the prevention of coronary restenosis after balloon angioplasty. The Dose-Finding Study Group. *N Engl J Med* 2001; 344: 243-9.
18. Sousa JE, Morice M, Serruys P, et al. The RAVEL study: a randomized study with the sirolimus coated BX velocity balloon expandable stent in the treatment of patients with de novo native coronary artery lesions. (abstr) *Circulation* 2001; 104: II-463.
19. Kuntz RE, Safian RD, Carrozza JP, Fishman RF, Mansour M, Baim DS. The importance of acute luminal diameter in determining restenosis after coronary atherectomy or stenting. *Circulation* 1992; 86: 1827-35.
20. Colombo A, Hall P, Nakamura S, et al. Intracoronary stenting without anticoagulation accomplished with intravascular ultrasound guidance. *Circulation* 1995; 91: 1676-88.
21. Stankovic G, Nishida T, Corvaja N, et al. Effect of balloon oversizing in stenting small vessels. (abstr) *J Am Coll Cardiol* 2001; 37: 73A.
22. Kastrati A, Schühlen H, Schomig A. Stenting for small coronary vessels: a contestable winner. *J Am Coll Cardiol* 2001; 38: 1604-7.
23. Koning R, Eltchaninoff H, Commeau P, et al. Stent placement compared with balloon angioplasty for small coronary arteries: in-hospital and 6-month clinical and angiographic results. *Circulation* 2001; 104: 1604-8.
24. Moer R, Myreng Y, Molstad P, et al. Stenting in small coronary arteries (SISCA) trial. A randomized comparison between balloon angioplasty and the heparin-coated beStent. *J Am Coll Cardiol* 2001; 38: 1598-603.
25. Prati F, Di Mario C, Moussa I, et al. In-stent neointimal proliferation correlates with the amount of residual plaque burden outside the stent: an intravascular ultrasound study. *Circulation* 1999; 99: 1011-4.
26. Aizawa T, Tamai H, Asakura Y, et al. Clinical and angiographic results of the Debulking and Stenting in Restenosis Elimination (DESIRE) trial. (abstr) *Circulation* 2001; 104: II-624.
27. Kleiman NS, Califf RM. Results from late-breaking clinical trials sessions at ACCIS 2000 and ACC 2000. American College of Cardiology. *J Am Coll Cardiol* 2000; 36: 310-25.
28. Sabate M, Costa MA, Kozuma K, et al. Geographic miss: a cause of treatment failure in radiooncology applied to intracoronary radiation therapy. *Circulation* 2000; 101: 2467-71.
29. Kim HS, Waksman R, Cottin Y, et al. Edge stenosis and geographical miss following intracoronary gamma radiation therapy for in-stent restenosis. *J Am Coll Cardiol* 2001; 37: 1026-30.
30. Waksman R, Bhargava B, Mintz GS, et al. Late total occlusion after intracoronary brachytherapy for patients with in-stent restenosis. *J Am Coll Cardiol* 2000; 36: 65-8.
31. Waksman R, Ajani AE, White RL, et al. Prolonged antiplatelet therapy to prevent late thrombosis after intracoronary gamma-radiation in patients with in-stent restenosis: Washington Radiation for In-Stent Restenosis Trial plus 6 months of clopidogrel (WRIST PLUS). *Circulation* 2001; 103: 2332-5.
32. Herdeg C, Oberhoff M, Karsch KR. Antiproliferative stent coatings: taxol and related compounds. *Semin Interv Cardiol* 1998; 3: 197-9.
33. Axel DI, Kunert W, Goggelmann C, et al. Paclitaxel inhibits arterial smooth muscle cell proliferation and migration in vitro and in vivo using local drug delivery. *Circulation* 1997; 96: 636-45.
34. Herdeg C, Oberhoff M, Baumbach A, et al. Local paclitaxel delivery for the prevention of restenosis: biological effects and efficacy in vivo. *J Am Coll Cardiol* 2000; 35: 1969-76.
35. Heldman AW, Cheng L, Jenkins GM, et al. Paclitaxel stent coating inhibits neointimal hyperplasia at 4 weeks in a porcine model of coronary restenosis. *Circulation* 2001; 103: 2289-95.
36. Honda Y, Grube E, de La Fuente LM, Yock PG, Stertz SH, Fitzgerald PJ. Novel drug-delivery stent: intravascular ultrasound observations from the first human experience with the QP2-eluting polymer stent system. *Circulation* 2001; 104: 380-3.
37. Kataoka T, Grube E, Hauptmann K, et al. Prevention of restenosis by a new drug eluting stent an intravascular ultrasound substudy of the SCORE trial. (abstr) *Circulation* 2001; 104: II-701.
38. Farb A, Heller PF, Shroff S, et al. Pathological analysis of local delivery of paclitaxel via a polymer-coated stent. *Circulation* 2001; 104: 473-9.
39. Grube E, Silber S, Hauptmann K. TAXUS 1 prospective, randomized, double blind comparison of NIRx™ stents coated with paclitaxel in a polymer carrier in de novo coronary lesions compared with uncoated controls. (abstr) *Circulation* 2001; 104: II-463.
40. Park S, Shim W, Ho D, et al. The clinical effectiveness of paclitaxel coated coronary stents for the reduction of restenosis in the ASPECT trial. (abstr) *Circulation* 2001; 104: II-464.
41. Gershlick A, Descheerder I, Chevalier B, et al. Local drug delivery to inhibit coronary artery restenosis. Data from ELUTES (evaluation of paclitaxel eluting stent) clinical trial. (abstr) *Circulation* 2001; 104: II-416.
42. Poon M, Marx SO, Gallo R, Badimon JJ, Taubman MB, Marks AR. Rapamycin inhibits vascular smooth muscle cell migration. *J Clin Invest* 1996; 98: 2277-83.
43. Gallo R, Padurean A, Jayaraman T, et al. Inhibition of intimal thickening after balloon angioplasty in porcine coronary arteries by targeting regulators of the cell cycle. *Circulation* 1999; 99: 2164-70.
44. Suzuki T, Kopia G, Hayashi S, et al. Stent-based delivery of sirolimus reduces neointimal formation in a porcine coronary model. *Circulation* 2001; 104: 1188-93.
45. Sun J, Marx SO, Chen HJ, Poon M, Marks AR, Rabbani LE. Role for p27(Kip1) in vascular smooth muscle cell migration. *Circulation* 2001; 103: 2967-72.
46. Marx SO, Marks AR. Bench to bedside: the development of rapamycin and its application to stent restenosis. *Circulation* 2001; 104: 852-5.
47. Sousa JE, Costa MA, Abizaid AC, et al. Sustained suppression of neointimal proliferation by sirolimus-eluting stents: one-year angiographic and intravascular ultrasound follow-up. *Circulation* 2001; 104: 2007-11.
48. Moses J, Leon M, Popma J, Kuntz R. The US multicenter, randomized, double blind study of the sirolimus eluting stent in coronary lesions: early (30 day) safety results. (abstr) *Circulation* 2001; 104: II-464.
49. Teirstein PS. Living the dream of no restenosis. *Circulation* 2001; 104: 1996-8.