

Focus on treatment of atrial fibrillation and flutter

(Ital Heart J 2004; 5 (Suppl 1): 124S-142S)

© 2004 CEPI Srl

QUANTITATIVE ANALYSIS OF THE VEIN DRAINAGE TO THE RIGHT ATRIUM BY CARDIOVASCULAR MAGNETIC RESONANCE IN PATIENTS WITH CHRONIC AND INTERMITTENT ATRIAL FIBRILLATION

Pablo I. Altieri, Edgar Colón,
José Rodríguez Orengo, Nelson Escobales,
Hector Banch, María Crespo,
Yolanda Figueroa

*Department of Medicine Radiology and Physiology,
University of Puerto Rico, Medical Sciences Campus,
San Juan, Porto Rico*

Atrial fibrillation is a complex arrhythmia, which may produce congestive heart failure by reducing the cardiac output by 30%, but the worst complication is systemic embolism^{1,2}. At present the management is chronic anticoagulation with coumadin, but also trying to convert the fibrillation to normal sinus rhythm. Methods to convert to normal sinus rhythm are cardioversion or pulmonary vein or atrial ablation. It is important to visualize the vein drainage to the right atrium in order to do these procedures. Several methods have been described such as intra-atrial echocardiography or angiography. We think magnetic resonance imaging (MRI) is a noninvasive method, which will clearly visualize the venous drainage to the right atrium in patients with chronic and intermittent atrial fibrillation and also visualize the left atrium. By visualizing the heart chambers, we can achieve with minimum complications the invasive ablation procedure.

Population

Fourteen patients (8 males, 6 females, mean age 60 years) underwent cardiovascular magnetic resonance with emphasis in the venous drainage to the right atrium, which includes quantitative analysis of the

right and left pulmonary veins, inferior and superior vena cava, and the right and left atria (Figs. 1-5). All were hypertensive with control of their blood pressure with drug treatment. None of them had had congestive heart failure; 7 had chronic atrial fibrillation and 7 intermittent atrial fibrillation. This group was compared with 3 normal subjects. The atrial fibrillation group was anticoagulated with coumadin. None had systemic embolisms. Seven patients with atrial fibrillation (chronic-intermittent) had positive C-reactive protein analysis.

The MRI studies were performed in a Philips machine with a 1.5 Tesla magnet. The heart was evaluated with the following pulse sequence; cardiac gated, T-1 weighted coronal and axial cine-GRE horizontal long axis (4-chamber view). Following this a gadolinium enhance magnetic resonance angiogram (MRI) was performed using a three-dimensional TUF sequence with emphasis on the pulmonary circulation. Images from the MRI were used to obtain measurements of the greatest diameters of the superior and inferior vena cava at the ostia, at the junction with the right atrium and similarly of the right and left superior pulmonary veins at the ostia near the junction with the left atrium. Images from the cine-GRE 4-chamber view were used to obtain two-dimensional measurements of both atria at end-systole (Figs. 1-5). Measurements were done in both atria from left to right axis and superior-inferior axis. The measurements were analyzed using two sample Wilcoxon rank sum (Mann Whitney), unpaired Student t-tests, parametric.

Results

Table I shows the results obtained in the measurement of the superior and inferior vena cava, right superior pulmonary vein, left superior pulmonary vein, left-right axis,

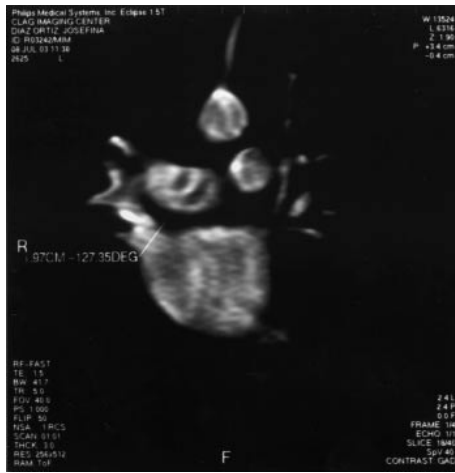

Figure 1. Measurement of the greatest diameter of the right pulmonary vein at the junction with the right atrium.

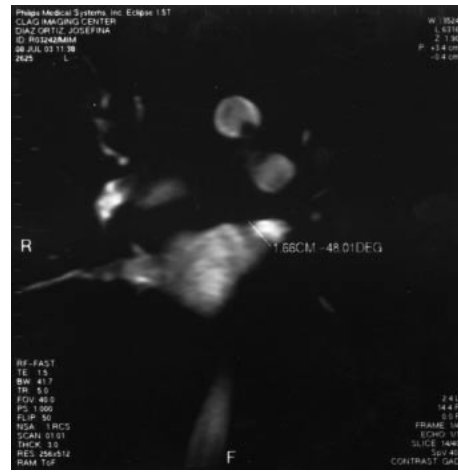


Figure 2. Measurement of the greatest diameter of the left pulmonary vein at the junction with the right atrium.

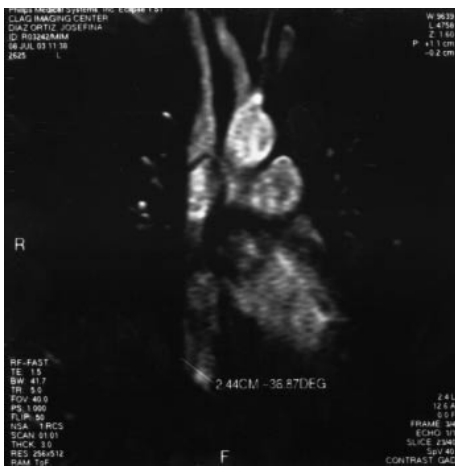

Figure 3. Measurement of the greatest diameter of the inferior vena cava at the junction to the right atrium and measurement of the right atrial axis.

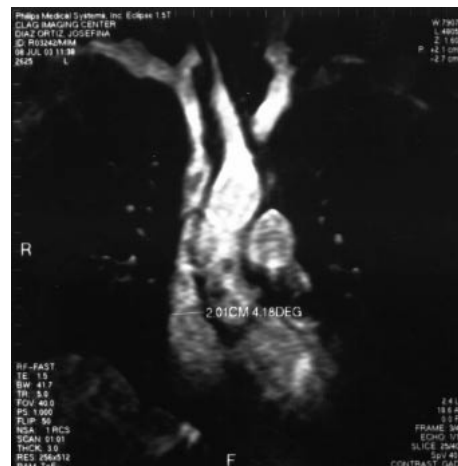

Figure 4. Measurement of the greatest diameter of the superior vena cava at the junction with the right atrium.

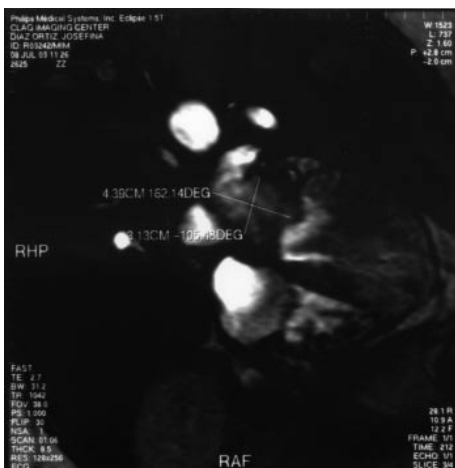


Figure 5. Measurement of the left atrial axis.

right superior-inferior axis of the right and left atrium in patients with intermittent and chronic atrial fibrillation. In the normal population the atria were not measured due

to technical problems with the protocol. As described in table I there were statistically significant changes ($p < 0.05$) in the left superior pulmonary vein diameter in patients between intermittent and chronic atrial fibrillation and in the right superior pulmonary vein diameter between intermittent atrial fibrillation and controls. Significant changes were seen in the inferior vena cava between controls and chronic atrial fibrillation and in the left superior pulmonary vein between controls and chronic atrial fibrillation. Figure 5 shows the left atrial measurements. In patients with chronic and intermittent atrial fibrillation no significant changes were seen.

Discussion

Atrial fibrillation is an arrhythmia being studied extensively due to the medical problems produced such as systemic embolisms, reduction of the cardiac output and the problem of chronic anticoagulation. Modern

Table I.

	Intermittent AF (n=7)	Chronic AF (n=7)	Normal subjects (n=3)
SVC (mm)	19.1 ± 1.83	19.1 ± 3.5	17 ± 0.2
IVC (mm)	27.8 ± 2.6	32.6 ± 9.1*	22.7 ± 4.56*
RSPV (mm)	19.4 ± 4.2*	17.8 ± 4.6*	14.5 ± 1.6*
LSPV (mm)	15.3 ± 1.3*	18.5 ± 2.8*	13.6 ± 1.3*
L-R axis of RA (mm)	43.4 ± 4.5	40.5 ± 9.2	–
S-I axis of RA (mm)	45.1 ± 5.9	42.8 ± 7.2	–
L-R axis of LA (mm)	56.9 ± 18.5	47.9 ± 9.3	–
S-I axis of LA (mm)	51.9 ± 14.2	50.7 ± 14.7	–

AF = atrial fibrillation; IVC = inferior vena cava; LA = left atrium; L-R = left-right; LSPV = left superior pulmonary vein; RA = right atrium; RSPV = right superior pulmonary vein; S-I = superior-inferior; SVC = superior vena cava. * $p < 0.05$.

electrophysiology has been, very aggressive in the management with ablation of the atrium and pulmonary veins³. The most important aspect in an ablation of these structures is to identify the ablation area prior to the procedure. Investigators have used intracardiac ultrasound imaging, magnetic resonance or angiography to identify these structures prior to the invasive procedure. This is followed by right atrial mapping and pulmonary veins to improve catheter-mediated ablation lines to control arrhythmia recurrences.

Several investigators have shown that dilation of the pulmonary veins or inferior-superior vena cava or left atrium may induce intermittent or chronic atrial fibrillation⁴⁻⁶. Investigators have suggested that this dilation is due to invasion of the atrial myocardium in the venous drainage of the right atrium, but the mechanism is not clear; probably angiotensin II has a role in this process.

It is fascinating to found a statistically significant dilation ($p < 0.05$) in the left superior pulmonary vein in patients with intermittent chronic atrial fibrillation and normal subjects. Also, in the right superior pulmonary vein between intermittent atrial fibrillation and normal subjects. There were significant dilation parameters in the inferior vena cava between chronic atrial fibrillation and normal subjects but not in intermittent atrial fibrillation.

Schwartzman et al.⁵ reported that left atrial and pulmonary veins were significantly larger in patients with atrial fibrillation versus normal subjects. Tsai et al.⁴ reported that ectopic beats initiating paroxysmal atrial fibrillation can originate from the superior vena cava. They suggested that the superior vena cava has cardiac musculature extending from the right atrium. Tsao and Chen⁷ showed a significant dilation of both superior pulmonary veins and transverse diameter of the left atrium in patients with atrial fibrillation. We observed bigger diameters in the left-right diameters in the right atrium in patients with intermittent atrial fibrillation compared with chronic atrial fibrillation, but the changes were not significant. Probably this initial dilation changes in the atrium will produce a chronic substrate for the initiation of chronic atrial fibrillation.

Yamane et al.⁶ found that in 40% of patients with atrial fibrillation the trigger came from the left superior pulmonary vein. This is consistent with our data. This datum points out that the foci for atrial fibrillation occurs in the venous drainage to the right atrium and possibly in both atria. The fascinating observation is why the myocardial muscle migrates to the junction of the veins and atrium producing an unstable electrophysiologic state at that junction.

The role of angiotensin II in this process is not known. We know that angiotensin II will produce migration of smooth muscle cell and proliferation from the adventitia to the endothelial surface; it is possible that angiotensin II will produce migration of the myocardial cells to the pulmonary vein by the same process.

We think that MRI is an excellent noninvasive tool to study the morphology of the right-left atrium and venous drainage to the atria. In order to plan the invasive management of this arrhythmia more investigation is needed to find out why these vessels are involved in the induction of atrial fibrillation. The limitation of this study is the few normals. This is due to the fact that in America it is difficult to justify this study in normal patients.

References

1. Krahn DD, Manfred J, Tate RB, et al. The natural history of atrial fibrillation: incidence, risk factors, and prognosis in the Manitoba follow up study. *Am J Med* 1995; 98: 476-84.
2. Psaty BM, Manolio TA, Kuller L, et al. Incidence and risk factors for atrial fibrillation in older adults. *Circulation* 1997; 96: 2455-61.
3. Goya M, Ouyang F, Ernsts, et al. Electroanatomic mapping and catheter ablation of breakthroughs from the right atrium to the superior vena cava in patients with atrial fibrillation. *Circulation* 2002; 106: 1317-20.
4. Tsai CF, Tai CT, Hsieh MH, et al. Initial of atrial fibrillation by ectopic beats originating from the superior vena cava; electrophysiological characteristics and results of radiofrequency ablation. *Circulation* 2002; 102: 67-74.
5. Schwartzman D, Laconis J, Wigginton WB. Characterization

of left atrium and distal pulmonary vein morphology using multidimensional computed tomography. *Am J Cardiol* 2003; 41: 1349-57.

6. Yamane T, Shah DC, Jais P, et al. Dilation as a marker of pulmonary vein initiating atrial fibrillation. *J Interv Card Electrophysiol* 2002; 3: 245-49.
7. Tsao HM, Chen SA. Evaluation of pulmonary vein stenosis after catheter ablation of atrial fibrillation. *Card Electrophysiol Rev* 2002; 6: 397-400.

ELECTRICAL CARIOVERSION OF ATRIAL FIBRILLATION: NEW TECHNIQUES AND DEVELOPMENTS

Bulent Gorenek

Cardiology Department, Osmangazi University School of Medicine, Eskisehir, Turkey

Electrical cardioversion has become a routine procedure in converting chronic atrial fibrillation to sinus rhythm. External and internal cardioversion methods can be used for termination of atrial fibrillation. Transthoracic impedance, position and size of electrodes and the type of waveforms applied are important factors affecting the success rate of the external cardioversion. Internal cardioversion is more effective than external technique and can be used in patients resistant to external cardioversion. The development in that method, such as single balloon catheter technique and transesophageal echocardiography guidance, made its use easier and shortened the duration of the procedure.

Atrial fibrillation (AF) is one of the most common, clinically important cardiac arrhythmias which needs careful evaluation and therapy. It often requires pharmacological or electrical therapy to restore sinus rhythm. Electrical cardioversion of patients with AF to normal sinus rhythm is frequently performed to relieve symptoms, improve cardiac performance and decrease the risk of embolic events.

Electrical cardioversion may be performed externally or internally. External method is used more commonly. It has been a successful technique for the treatment of AF ever since its introduction in the 1960s by Lown¹. In most series electrical cardioversion has an initial success rate of 80-90% depending on the population studied. However, the relative importance of factors determining the success rate and energy requirement has not been established. A number of factors, other than patient's characteristics, are also important for the efficacy of cardioversion. Electrode position, the type of waveforms, transthoracic impedance may affect the success of cardioversion. Optimal electrode position is important because a critical mass of atrial muscle must be depolarized for cardioversion to occur. There are three conventional electrode positions: anterolateral

orientation, anteroanterior orientation, and anteroposterior orientation. Although several studies have suggested that less energy is required and the success rate is higher with the anteroposterior electrode position^{2,3}, some reports have failed to confirm these findings^{4,5}. Electrode pad size is another important determinant of transthoracic current flow during external countershock. A larger paddle surface is associated with a decrease in resistance⁶. Paddles smaller than 8 cm and larger than 12.8 cm are not recommended for electrical cardioversion of AF. Monophasic or biphasic shocks are delivered due to type of the defibrillator used. Clinical studies have shown that biphasic shocks are more effective than monophasic shocks for termination of AF. Rectilinear biphasic shocks also require less energy than sine wave monophasic shocks⁷. Especially in the presence of high transthoracic impedance biphasic waveforms are superior to monophasic waveforms⁷. With the greater efficacy of biphasic shocks, it is likely that there will be a smaller difference in the success rates of electrode positions and size than when monophasic shocks are used.

Internal cardioversion, using low energy may restore sinus rhythm in patients with AF⁸. This method has been used when conventional external cardioversion fails or in patients with high transthoracic impedance and/or contraindications to general anesthesia. It is commonly applied by using two catheters, inserting one into the right atrium and the other into either the coronary sinus or the left pulmonary artery. A single lead cardioversion technique, which has such advantages as ventricular back-up pacing and reducing fluoroscopy exposure can also be used⁹ (Figs. 1 and 2). Internal cardioversion of AF under transesophageal echocardiography (TEE) guidance without fluoroscopy using single lead catheter technique is another new method of cardioversion¹⁰ (Fig. 3). Single balloon catheter can be applied under TEE guidance, avoiding the use of fluoroscopy, and can facilitate the insertion of the catheter into the left pulmonary artery. It appears to have two advantages over fluoroscopy in terms of convenience.

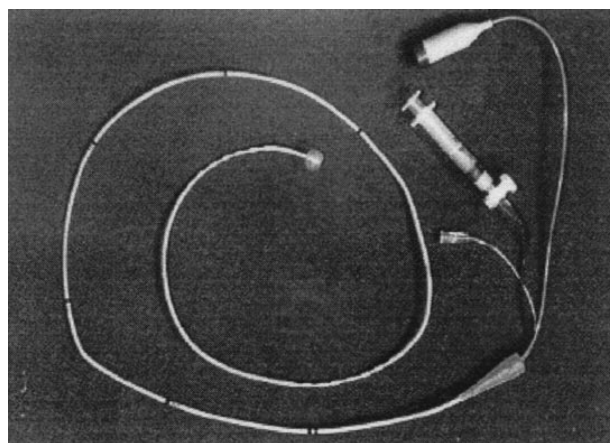


Figure 1. Single lead balloon catheter used in internal cardioversion of atrial fibrillation¹⁰.

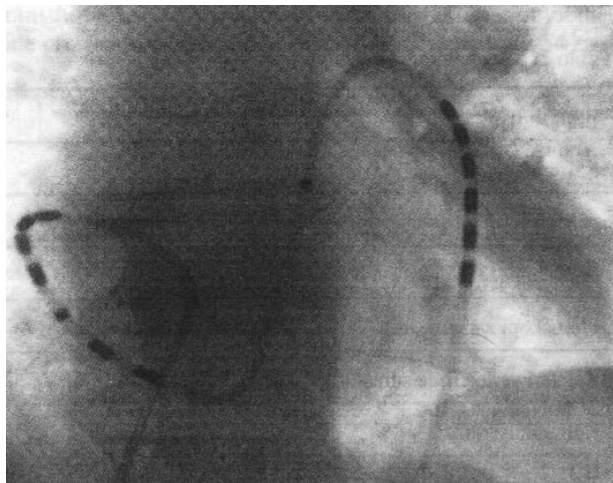


Figure 2. Catheter placement during single lead cardioversion.

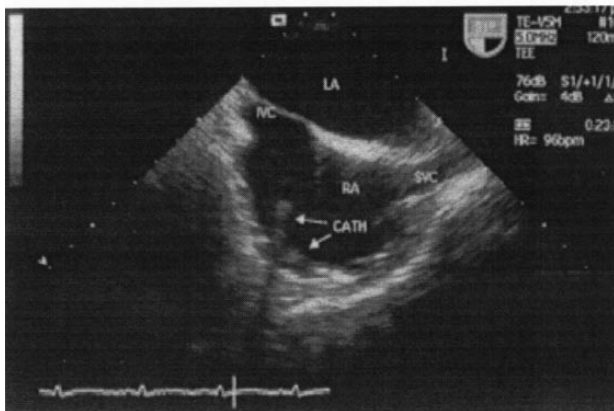
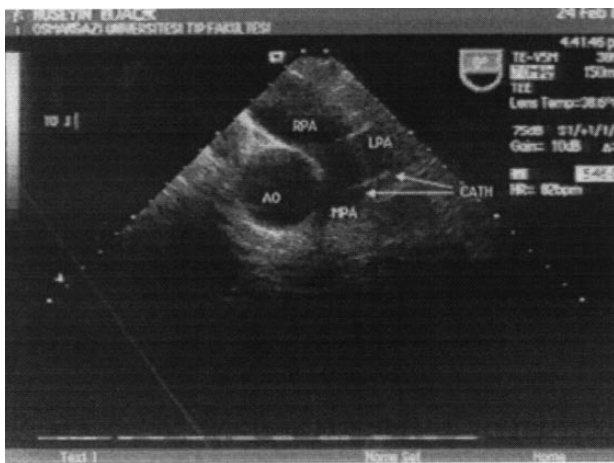


Figure 3. Transesophageal echocardiographic view of the cardioversion catheter placed in left pulmonary artery¹⁰. AO = aorta; cath = catheter; IVC=inferior vena cava; LA = left atrium; LPA = left pulmonary artery; MPA = main pulmonary artery; RA = right atrium; RPA = right pulmonary artery; SVC = superior vena cava.

First, because the takeoff where the right and left pulmonary arteries fork can be viewed by TEE, it may be much easier to direct the catheter into the left pulmonary artery. Second, touching the catheter against the right atrial wall diminishes the defibrillation threshold.

Internal cardioversion of AF, when combined with some measurements techniques may help us in understanding of the mechanisms responsible for recurrence of AF^{11,12} (Fig. 4). Low-energy cardioversion with epicardial wire electrodes is a safe and effective method to convert AF after open heart surgery. The shock energy required to restore sinus rhythm is very low in that method and patients can be converted without anesthesia¹³.

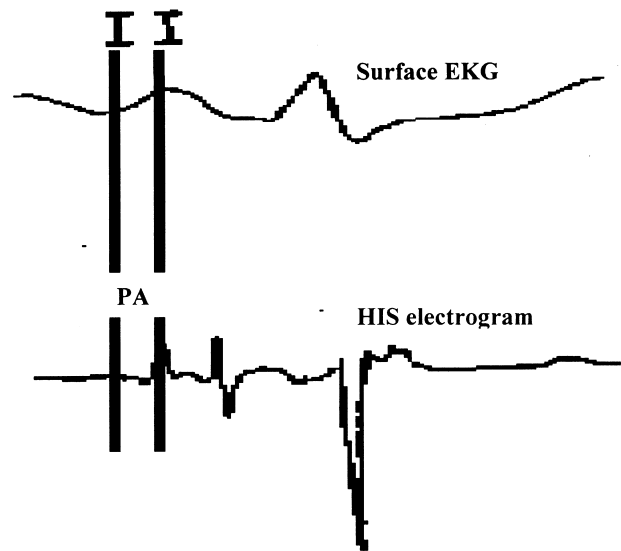


Figure 4. Measurement of P-A interval just after successful internal cardioversion of atrial fibrillation. The patients who had more pronounced P-A interval variation developed more immediate recurrence of atrial fibrillation¹¹.

References

1. Lown B. New method for terminating cardiac arrhythmias. JAMA 1962; 3: 548-55.
2. Botto GL, Politi A, Bonini W, et al. External cardioversion of atrial fibrillation: role of paddle position on technical efficacy and energy requirements. Heart 1999; 82: 726-30.
3. Kirchhof P, Eckardt L, Loh P, et al. Anterior-posterior versus anterior-lateral electrode positions for external cardioversion of atrial fibrillation: a randomised trial. Lancet 2002; 360: 1275-9.
4. Alp NJ, Rahman S, Bell JA, Shahi M. Randomised comparison of antero-lateral versus antero-posterior paddle positions for DC cardioversion of persistent atrial fibrillation. Int J Cardiol 2000; 75: 211-6.
5. Mathew TP, Moore A, McIntyre M, et al. Randomised comparison of electrode positions for cardioversion of atrial fibrillation. Heart 1999; 81: 576-9.
6. Kuelberg J. The interelectrode electrical resistance at defibrillation. Scand J Thorac Cardiovasc Surg 1972; 6: 274-9.
7. Mittal S, Ayati S, Stein KM, et al. Transthoracic cardioversion of atrial fibrillation: comparison of rectilinear biphasic versus damped sine wave monophasic shocks. Circulation 2000; 101: 1282-7.
8. Levy S, Ricard P, Gueunoun M, et al. Low-energy cardioversion of spontaneous atrial fibrillation. Immediate and long-term results. Circulation 1997; 96: 253-9.
9. Alt E, Armer R, Lehman G, Schmitt C, et al. Efficacy of new balloon catheter for internal cardioversion for chronic atrial fibrillation without anesthesia. Heart 1998; 79: 119-27.

10. Goktekin O, Melek M, Timuralp B, et al. Internal cardioversion of atrial fibrillation under transesophageal echocardiography guidance without fluoroscopy using single lead catheter technique. *Am J Cardiol* 2002; 90: 328-31.
11. Gorenek B, Kudaiberdieva G, Cavusoglu Y, et al. Immediate recurrence of atrial fibrillation after internal cardioversion: importance of right atrial conduction variations. *J Electrocardiol* 2002; 35: 313-20.
12. Korte T, Niehaus M, Borchet G, Tebbenjohanns J. Significant prolongation of atrial monophasic action potential duration: short-term reverse electrophysiological changes after internal cardioversion of atrial fibrillation. *Cardiovasc Res* 2002; 53: 944-51.
13. Liebold A, Wahba A, Birnbaum DE. Low-energy cardioversion with epicardial wire electrodes: new treatment of atrial fibrillation after open heart surgery. *Circulation* 1998; 98: 883-6.

PULMONARY VEIN ISOLATION IN ATRIAL FIBRILLATION ABLATION: THE ROLE OF LOCALISA THREE-DIMENSIONAL NAVIGATION SYSTEM

Giuseppe Inama, Ornella Durin, Pietro Agricola, Giulio Romagnoli, Massimiliano Nanetti, Claudio Pedrinazzi

Division of Cardiology, Maggiore Hospital, Crema, Italy

Atrial fibrillation, the most common sustained arrhythmias encountered in clinical practice, is associated with several manifestations ranging from palpitation to heart failure. The intracardiac navigation system Localisa is a novel system that allows the three-dimensional representation of the heart space and therefore has the potential to partially replace fluoroscopy during catheter ablation procedures. With this system it is possible to return precisely in each moment of a procedure to an anatomic/electrophysiologic marker previously found.

The aim of the study was to evaluate the efficacy and safety of pulmonary vein (PV) ablation using the new non-fluoroscopic navigation system for accurate, real-time three-dimensional localization of intracardiac electrodes. We used in our Electrophysiology Laboratory the Localisa system in 86 patients during ablation procedure for supraventricular tachyarrhythmias as atrial flutter, atrioventricular nodal reentrant tachycardia, atrial tachycardia and atrial fibrillation. In 6 patients with drug refractory atrial fibrillation (preliminary experience) who underwent PV ablation we used the Localisa navigation system for real-time non-fluoroscopic imaging of the lasso and the ablation catheter electrodes. We achieved the electrophysiologic endpoint for all PV in all the patients. The average procedure time was 210 min (range 180-240 min), the average fluoroscopy time was 42 min (range 35-60 min) and the average radiofrequency-PV disconnection time was 23 min (range 18-30 min) in accordance with the published studies that documented a significant reduction of the procedural and fluoroscopy time using Localisa.

The non-fluoroscopic catheters localization using a Localisa imaging system allows an accurate mapping during radiofrequency procedures and the creation of linear lesions reducing the fluoroscopy exposure time.

Introduction

Atrial fibrillation (AF) is the most common sustained arrhythmias encountered in clinical practice with a prevalence of 5% over the age of 65 years¹. It is associated with several manifestations ranging from palpitation to heart failure. The present pharmacological treatment is difficult and characterized by frequent recurrences, drug-related side effects and possible proarrhythmias. Several studies have shown that AF may originate from atrial myocardial located into the pulmonary veins (PV)^{2,3}. It was recently reported that electrical PV disconnection is possible by radiofrequency (RF) energy delivered in the PV⁴⁻⁶. The ablation procedure, still under investigation, is complex, time-consuming and is frequently associated with high exposure to ionizing radiation during the ablation and during the basal electrophysiological study^{7,8}.

The intracardiac navigation system Localisa (Medtronic Inc. Minneapolis, MN, USA), is a system that allows the three-dimensional vision of the heart space and therefore has the potential to partially replace fluoroscopy during catheter ablation procedures. With this system it is possible to return precisely in each moment of a procedure to an anatomic/electrophysiologic marker previously found⁹⁻¹¹.

The aim of the study was to evaluate the efficacy and safety of PV ablation using the new non-fluoroscopic navigation system for accurate, real-time three-dimensional localization of intracardiac electrodes. The Localisa system can display the three-dimensional position of intracardiac catheters by measuring three low-amplitude high-frequency currents applied orthogonally to each other through the thorax. We evaluated if the use of this novel system significantly reduces the radiation exposure and facilitates the electrical disconnection of the PV.

The Localisa produces an electric field (by 3 low intensity currents) involving the heart, where a moving electrode can measure different potentials with regard to its different position. When an intracardiac electrode is connected to the system, the value of the electric potential is measured in each of the three direction of the space. In this way Localisa visualizes in real-time the position of the electrode in a system of coordinates X-Y-Z.

The Localisa system allows:

- positioning anatomic/electrophysiologic markers;
- returning with a catheter for electrophysiology into a 2 mm radius from each anatomic/electrophysiologic marker previously found;
- visualizing up to 10 electrodes simultaneously;
- associating an activation time to any acquired point;
- associating to each ablation marker the values relative to the application of RF of the Atakr II generator.

The group of Bordeaux¹²⁻¹⁴ documented a significant reduction in fluoroscopy time for disconnection of all four pulmonary veins using the Localisa navigation system.

Methods

We used in our Electrophysiology Laboratory the LocaLisa system in 86 patients during ablation procedure for atrial flutter, atrioventricular nodal reentrant tachycardia, atrial tachycardia and AF.

In 6 patients with drug-refractory AF (preliminary experience) who underwent PV ablation we used the LocaLisa navigation system for real-time non-fluoroscopic imaging of the lasso and the ablation catheter electrodes. A 6F quadripolar catheter was introduced in the coronary sinus through left subclavian vein. A 6F LocaLisa catheter was screwed in the right atrial appendage. The PV mapping was performed using a decapolar steerable circular catheter 15 or 20 mm in diameter with 1 mm electrodes (lasso catheter, Biosense Webster). The ablation catheter was a Medtronic RF Sprinklr single curve distal tip irrigated 4 mm. The RF energy was delivered through a Medtronic Atakr II generator with a power limit of 25 W. The lasso catheter was

positioned just inside the PV ostium, and was marked by the LocaLisa system. The site of the electrical breakthrough to the PV ostium was determined from the lasso recordings, and the ablation catheter was manipulated around the ostium to apply RF energy and marked by the LocaLisa system, reducing the fluoroscopy exposure. The PV isolation was performed by circumferential ablation around the ostia with the endpoint of electrophysiologic disconnection of the left atrium from the PV (Figs. 1 and 2).

Results and discussion

We achieved the electrophysiologic endpoint for all PV in all the patients.

The average procedure time was 210 min (range 180-240 min), the average fluoroscopy time was 42 min (range 35-60 min) and the average RF-PV disconnection time was 23 min (range 18-30 min) in accordance with

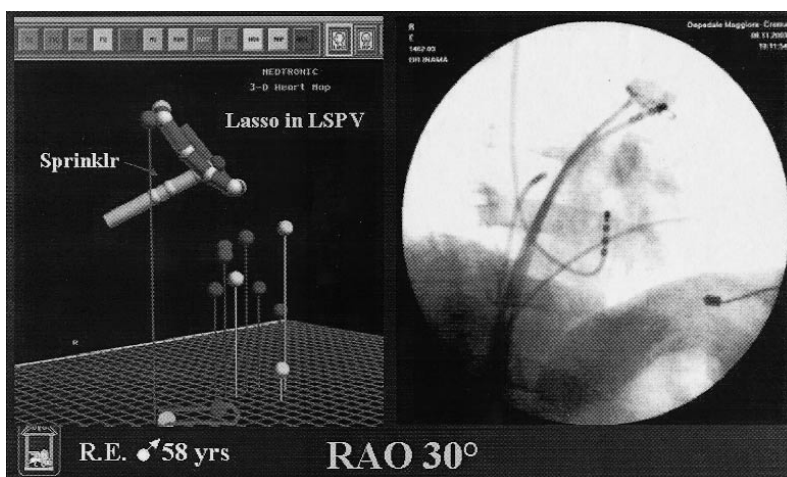


Figure 1. Left panel: the LocaLisa display with the lasso catheter inside the left superior pulmonary vein (LSPV) and the ablation catheter positioned near the pulmonary vein ostium. Right panel: right atrial oblique (RAO) 30° fluoroscopy view with the symmetric position of the catheters as in the LocaLisa system.

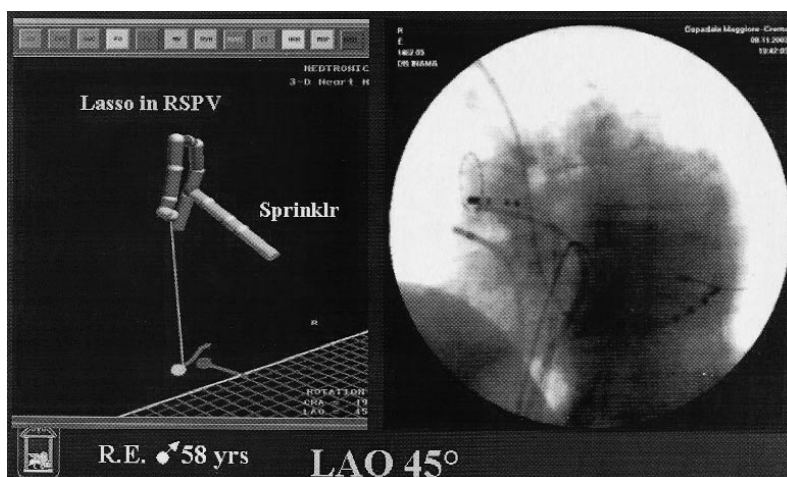


Figure 2. Left panel: LocaLisa display with the lasso catheter inside the right superior pulmonary vein (RSPV) with the ablation catheter. Right panel: the left atrial oblique (LAO) 45° fluoroscopy view shows the position of the catheters identical to the LocaLisa system.

the published studies that documented a significant reduction of the procedural and fluoroscopy time using LocaLisa.

The LocaLisa system allows the three-dimensional non-fluoroscopic visualization of intracardiac catheters and the accurate mapping during RF procedure with the creation of circumferential linear lesion. The possibility of continuous real-time visualization of the position and orientation of the lasso catheter and of the ablation catheter during the procedure reduces the need of fluoroscopy. The oblique views can be also used with LocaLisa during ablation with a possibility of visualization of the correct position of the ablation catheter during RF delivery without fluoroscopy. We did not have any complication during and after the procedures.

In conclusion, the non-fluoroscopic catheters localization using a LocaLisa imaging system allows an accurate mapping during RF procedures and the creation of linear and circumferential lesions reducing the fluoroscopy exposure time. The LocaLisa navigation system during RF pulmonary veins ablation for AF treatment facilitates the RF isolation of the PV. Moreover it allows the real time three-dimensional imaging of the mapping lasso catheter, the ablation catheter position and orientation reducing the need of fluoroscopy for PV disconnection.

References

1. Zipes DP. The seventh annual Gordon K. Moe Lecture. Atrial fibrillation: from cell to bedside. *J Cardiovasc Electrophysiol* 1997; 8: 927-38.
2. Haissaguerre M, Jais P, Shah DC, et al. Spontaneous initiation of atrial fibrillation by ectopic beats originating in the pulmonary veins. *N Engl J Med* 1998; 339: 659-66.
3. Haissaguerre M, Jais P, Shah DC, et al. Electrophysiological endpoint for catheter ablation of atrial fibrillation initiated from multiple pulmonary venous foci. *Circulation* 2000; 101: 1409-17.
4. Jais P, Weerasooriya R, Shah DC, et al. Ablation therapy for atrial fibrillation (AF). Past, present and future. *Cardiovasc Res* 2002; 54: 337-46.
5. Oral H, Knight BP, Tada H, et al. Pulmonary vein isolation for paroxysmal and persistent atrial fibrillation. *Circulation* 2002; 105: 1077-81.
6. Mangrum JM, Mounsey JP, Kok LC, DiMarco JP, Haines DE. Intracardiac echocardiography-guided, anatomically based radiofrequency ablation of focal atrial fibrillation originating from pulmonary veins. *J Am Coll Cardiol* 2002; 39: 1964-72.
7. Park TH, Eichling JO, Schechtman KB, et al. Risk of radiation induced skin injuries from arrhythmia ablation procedures. *Pacing Clin Electrophysiol* 1996; 19: 1363-9.
8. Koor P, Ricciardello M, Collins L, et al. Risk to patient from radiation associated with radiofrequency ablation for supraventricular tachycardia. *Circulation* 1998; 98: 1534-40.
9. Wittkampf FH, Wever EF, Derksen R, et al. LocaLisa: new technique for real-time 3-dimensional localization of regular intracardiac electrodes. *Circulation* 1999; 99: 1312-7.
10. Kirchhof P, Loh P, Eckardt L, et al. A novel nonfluoroscopic catheter visualization system (LocaLisa) to reduce radiation exposure during catheter ablation of supraventricular tachycardias. *Am J Cardiol* 2002; 90: 340-3.
11. Kanagaratnam L, Tomassoni G, Schweikert R, et al. Empirical pulmonary vein isolation using a three dimensional nonfluoroscopic mapping system: long term follow-up. *Pacing Clin Electrophysiol* 2001; 24: 1774-9.
12. Weerasooriya R, Macle L, Jais P, Hocini M, Haissaguerre M. Pulmonary vein ablation using the LocaLisa nonfluoroscopic mapping system. *J Cardiovasc Electrophysiol* 2003; 14: 112.
13. Macle L, Jais P, Scavee C, et al. Pulmonary vein disconnection using the LocaLisa three-dimensional nonfluoroscopic catheter imaging system. *J Cardiovasc Electrophysiol* 2003; 14: 693-7.
14. Scavee C, Weerasooriya R, Jais P, Hocini M, Haissaguerre M. Linear ablation in the left atrium using a nonfluoroscopic mapping system. *J Cardiovasc Electrophysiol* 2003; 14: 554.

SAFETY AND EFFICACY OF CRYOABLATION CATHETER FOR THE TREATMENT OF ATRIAL FLUTTER: ACUTE AND LONG-TERM RESULTS

Annibale S. Montenero, Nicola Bruno, Andrea Antonelli, Daniele Mangiameli, Olive Murphy*, Stephen O'Connor*, Francesco Zumbo

*Cardiology Department and Arrhythmia Center, Policlinico MultiMedica, Sesto S. Giovanni (MI), Italy; *CryoCath Technologies Inc., Kirkland, Canada*

The aim of this study was to investigate the safety and efficacy of percutaneous cryoablation catheter in symptomatic atrial flutter patients. Percutaneous radiofrequency ablation of the isthmus between the tricuspid annulus and the inferior vena is an accepted therapy for symptomatic patients with atrial flutter. Percutaneous cryoablation catheter has been reported for the treatment of a variety of arrhythmias and is associated with preservation of tissue architecture, minimal thrombus formation, lack of pain and avoidance of collateral damage to other structures on energy delivery.

We have investigated the cryoablation of 98 consecutive symptomatic patients with atrial flutter. Electrophysiological studies were performed with diagnostic catheters and ablations performed with Freezor Xtra (CryoCath, Kirkland, Canada), a 7F, 6 mm tip, quadripolar cryo catheter. We assessed the appropriateness of a site for ablation with test freezes around the inferior rim of the coronary sinus os, and, if found to be suitable, 4-6 min applications of cryo were administered at -75°C. The endpoint was defined by bidirectional isthmus block. Our technique eradicated the need to create a complete flutter line. Acute success was achieved in 85.7% of patients, increasing to 92.1% with experience in patients with common atrial flutter; 55 patients successfully ablated were all symptom-free at 3 months, although on repeat electrophysiological study, 30.9% were found to have a conduction recurrence. There were no adverse events and all patients remained discomfort-free on cryo delivery.

In conclusion, cryoablation for atrial flutter is a safe, efficacious and pain-free treatment for atrial flutter.

Introduction

Radiofrequency (RF) ablation is widely used to cure symptomatic patients with common atrial flutter (AFI) by ablating the isthmus between the tricuspid annulus and the inferior vena cava¹.

This well-established target is commonly known as the cavo-tricuspid isthmus (CTI)^{2,3}. Prior surgical experience⁴⁻⁶ has demonstrated that the area responsible for an arrhythmia can be successfully ablated by freezing with a hand held probe, leading to proposals of percutaneous cryoablation as an alternative and novel approach. The feasibility of this approach was proven by Dubuc et al. in 1998⁷. Cryo energy has been used to treat a number of arrhythmias in both adult and pediatric populations such as atrioventricular nodal reentrant tachycardia^{8,9}, accessory pathways¹⁰⁻¹³ and AFI¹⁴. Timmermans et al.¹⁴ compared RF energy with cryo energy delivered from a 10F 6 mm tip catheter for the treatment of AFI in a randomized manner. Cryothermal lesions are hypothermic lesions, created when heat is removed from the myocardium by the catheter, contrasting with hyperthermic lesions produced by other energy sources including RF, lasers, microwaves and ultrasound.

The cryo therapy effect is heterogeneous and is influenced by the proximity of cells to the catheter tip. Cells that are subjected to tissue temperatures < 5°C have a high probability of dying. Some cells, subjected to temperatures > 5°C at the periphery of the lesion area, experience a hypothermic effect, which results in a transient electrical effect. Electrical conduction slows with the application of cryo energy but returns to normal on rewarming. With cryo, it is possible to use this reversibility feature to test the suitability of a site for ablation without causing a permanent electrophysiological effect. Other benefits associated with cryo lesions include the preservation of the underlying tissue architecture and minimal thrombus formation¹⁵.

Cryolesions created at -75°C are as deep as RF lesions, but more focused, which is important when ablating near critical electrophysiological structures and coronary vessels; nevertheless this may be a limitation when creating a line across the isthmus in the established manner.

The aim of this study was to investigate the efficacy and safety of cryo energy delivered through a 7F catheter for percutaneous ablation of AFI, as well long-term efficacy.

Methods

Demographic characteristics. The study population consisted of 98 consecutive symptomatic AFI patients who were referred to our institute to undergo ablation for recurrent AFI between May 2002 and May 2003. The local ethics committee approved the protocol and an informed consent was obtained from all patients prior

to the procedure. All patients had previously been treated for AFI with two or more drug regimens at the time of the ablation. Eligibility for ablation required that all patients had at least two documented symptomatic episodes of AFI recorded either with ECG or Holter monitoring.

Antiarrhythmic drugs were withdrawn in all patients at least one week prior to ablation, with the exception of amiodarone, which was withdrawn 8 weeks prior to intervention. Follow-up data at 3 months post-ablation were received from 55 patients who were successfully ablated at intervention.

Data collection. All intervention and follow up data were collected at our institute and sent to the CryoCath International Patient Registry for analysis.

Definitions. The following definitions are used in this report:

- *common AFI* is a typical macro reentrant atrial arrhythmia, consistent with negative "F" waves in the inferior leads of the ECG and counterclockwise right atrial endocardial activation;
- *uncommon AFI* is a typical macro reentrant atrial arrhythmia, consistent with positive flutter waves in the inferior leads and negative flutter waves in V₁ and V₂ leads;
- *test freeze* is defined as cryo energy delivery for up to 60 s at -75°C whilst monitoring intracardiac electrograms for isthmus block;
- *cryoablation* is defined as a 4-6 min application of cryo energy at -75°C;
- *complete bidirectional conduction block* across the CTI, the criterion for successful cryoablation of AFI, was evaluated by pacing and recording the resultant electrograms at the following sites:
 - pacing the atrium at the coronary sinus (CS) immediately adjacent to the line of block (CS os) and recording at the lateral free wall (AL1). If the resultant atrial activation on the opposite side of the line of block at AL1 is late, this indicated that the wave of depolarization must proceed around the entire right atrium in a counterclockwise direction to the opposite side of the line of block, demonstrating CTI block;
 - pacing from AL1 on the lateral free wall and recording at the CS os. This confirmed that the resultant atrial activation at the CS os is late, indicating that the wave of depolarization must proceed around the entire right atrium in a clockwise direction to the opposite side of the line of block;
- *time to effect (s)* is defined as the length of time required to observe an electrophysiological change in the pathway being ablated.

Catheters. *Diagnostic.* A 7F, 24-pole catheter (Orbiter, USCI-Bard Inc., USA) with alternating 2-7-2 mm inter-electrode distance was placed, via the right femoral vein, into the trabeculated right atrium to simultaneously

record electrical activity in the right atrial free wall, the atrial roof and the anterior septum. A 10-pole catheter (USCI-Bard Inc.) was placed in the CS via the left subclavian vein for recording the LA and part of the infero-posterior atrial septum. A 10-pole catheter with 2 mm interelectrode spacing was inserted via the right femoral vein and positioned along the atrial septum in the His bundle region.

Ablation. In all cases we used a commercially available 7F deflectable, quadripolar catheter with a 6-mm tip electrode, Freezor $\text{\textcircled{D}}$ Xtra (CryoCath Inc., Kirkland, Canada) available with 49, 55 and 60 mm reach. Cooling of the catheter is facilitated through delivery of nitrous oxide to the tip, whereupon a phase change from liquid to gas occurs with a subsequent temperature reduction to approximately -75°C at the isthmus. The cryo catheter is connected to a console via an electrical cable and gas umbilical tube. The gas umbilical provides a lumen for the warmed, vaporized nitrous oxide to be returned to the cryo console under constant vacuum, whereas the electrical umbilical wire allows intra cardiac electrograms to be recorded from the electrophysiological system and safety functions to be displayed on the console.

Electrogram recording. Bipolar intracardiac electrograms filtered between 30 and 250 Hz were digitally recorded and stored on a Lab System 3.57 (Bard), simultaneously with a 3-lead surface ECG. Digital calipers were used to calculate atrial activation times in sinus rhythm and the AFL cycle length (F-F intervals).

Baseline electrophysiological study. A baseline electrophysiological study (EPS) was performed in all patients to exclude any other electrophysiological disorder, which could be responsible for their episodes of AFL. This EPS was performed with all patients in sinus rhythm and a non-sedated state. All patients received local anesthesia with lignocaine. Pacing was delivered via by the Orbiter catheter placed close to the right atrial auricula at twice the diastolic threshold with a 2 ms pulse width.

Induction of atrial flutter. During the baseline EPS, sustained or non-sustained AFL was induced by programmed atrial stimulation in order to identify patterns of activation consistent with uncommon forms of AFL or rapid atrial tachycardia. It was possible to induce AFL in approximately 90% of our patient group. Thereafter, atrial pacing at cycle length 20% shorter than the AFL cycle length was used to perform concealed entrainment and terminate AFL. In the remaining 10% of patients where AFL could not be induced, we moved directly to isthmus site evaluation and subsequent ablation.

Catheter position and ablation protocol. The ablation catheter was initially placed under fluoroscopic guidance (45° left atrial oblique and right atrial oblique projections) at the posterior isthmus close to the CS os. The cryoab-

lation catheter was placed to ensure a stable catheter position with a good electrode-endocardium contact, confirmed by stable intra-cardiac electrograms.

Conduction through the isthmus was evaluated by continuous pacing from CS os at cycle lengths of 600 ms and twice the diastolic threshold. Atrial activation was continuously recorded throughout the procedure by the Orbiter diagnostic catheter. A test freeze was initially applied for a maximum of 60 s. If no isthmus block was observed during this test freeze, cryo energy delivery was stopped and the catheter moved slightly to another site and the suitability for ablation of the new site assessed with a test freeze. If however, time to effect was < 60 s, cryoablation was continued typically for 4 to 6 min at -75°C . Bidirectional conduction block along the isthmus defined the endpoint of the ablation procedure and was assessed by pacing the atrium from the CS os and sensing on the lateral wall, and vice-versa as described earlier. Our methodology allowed for a waiting time of 30 min following successful ablation to ensure CTI block remained.

Statistical analysis. Continuous variables are expressed as mean \pm SD and compared using the Fishers exact test and Wilcoxon rank sum test¹⁶. SAS version 8.0 was used for all statistical analysis. For the two-sample t-tests, we used PROC TTEST, with no non-default options. For the Fisher's exact tests, we used PROC FREQ with the EXACT option. All tests were two-sided, tested at the 0.05 significance level.

Results

Demographics. The study population consisted of 98 consecutive symptomatic AFL patients. The mean age and arrhythmia duration were 61.5 ± 11.4 and 3.4 ± 8.5 years respectively. Demographic characteristics are shown in table I.

Cryoablation catheters. Freezor $\text{\textcircled{R}}$ Xtra cryo catheters were used in all 98 procedures. The 55 mm reach was used in 45 (45.9%) patients, whilst the 60 mm reach catheter was each used in 53 (54.1%) patients. A second catheter was used in 8 (8.2%) cases, as a longer reach than initially anticipated was required.

Acute success rate. *Acute success rate for all patients.* Acute success was achieved with cryo energy in 84 (85.7%) of 98 consecutive AFL patients. The success rate differentiated for common and uncommon AFL is shown in table II. Success rate was statistically significantly higher ($p = 0.01$) for common AFL.

RF was used in 2 (14.3%) of 14 patients where cryo energy was not successful and was only successful in 1 (50%).

Cryo energy was successful in 19 (90.5%) of 21 patients and in 7 (77.8%) of 9 patients who had previously undergone RF ablation and cryoablation for the same arrhythmia, respectively.

Table I. Demographic characteristics.

Sex (M/F)	57 (58.2%)/41 (41.8%)
Common AFI	90 (91.8%)
Uncommon AFI	8 (8.2%)
Previous RF ablation	9 (9.2%)
Previous cryoablation	21 (21.4%)
Prior pacemaker implant	2 (2.0%)
Prior ICD implant	3 (3.1%)
LVEF (%)	
> 60	75 (76.5%)
35-60	13 (13.3%)
25-34	5 (5.1%)
< 25	1 (1.0%)
Not measured	4 (4.1%)

AFI = atrial flutter; ICD = implantable cardioverter defibrillator; LVEF = left ventricular ejection fraction; RF = radiofrequency.

Table II. Atrial flutter (AFI) ablation success.

Type of AFI	Success (n=)	p
Uncommon	4 (50.0%)	0.01*
Common	80 (88.9%)	

* Fishers exact test.

Acute success with increasing cryo experience. We considered the effect of our increasing experience on our success rates and found that there was a trend towards increasing success rates with increasing experience, as shown in table III, which was statistically significant for the common AFI patients.

Number of cryo tests and cryoablations. The mean number of cryo tests and cryoablations was 24.4 ± 18.6 and 18.1 ± 20.9 , respectively. The mean number of test applications and ablations for successful and non-successful cases is shown in table IV. The large number of cryo tests reflects our practice of assessing the suitability of a site for ablation for up to 60 s. This led to a highly statistically significant decrease in the number of ablations that we performed after our initial 14 patients as shown in table V.

Intervention timings. The mean procedure time, fluoroscopy time and cryo application time for all patients was 88.1 ± 48.0 , 25.6 ± 12.5 and 45.6 ± 23.3 min, respectively. Procedure time, fluoroscopy time and cryo application times are shown in table VI together with a breakdown for our initial 14 patients and late 84 patients. There was a statistically significant reduction in all three timings following our initial experience.

Safety at intervention. There were no reported adverse events. There was no incidence of cryo-induced permanent atrioventricular block. None of the 98 (100%) patients experienced discomfort on cryo energy delivery.

Table III. Cryo success and number of cryoablations performed.

	Success	p
No. cryoablations performed		
< 15 AFI cases	10 (71.4%)	0.1*
> 15 AFI cases	74 (88.1%)	
No. common AFI ablations performed		
< 15 AFI cases	10 (71.4%)	0.05*
> 15 AFI cases	70 (91.2%)	

AFI = atrial flutter. * Fishers exact test.

Table IV. Number of cryo tests and ablations.

Cryo application	Success	Unsuccessful
Test	24.2 ± 19.2	26.4 ± 13.0
Ablate	16.1 ± 19.0	37.1 ± 28.7
Cryo applications	28.2 ± 19.2	35.8 ± 23.3

Data are expressed as mean \pm SD.

Table V. Learning experience an number of tests and ablations applied.

	< 15 AFI cases	\geq 15 AFI cases	p
No. cryoablations performed	33.4 ± 15.7	14.5 ± 20.3	0.001

AFI = atrial flutter.

Table VI. Procedure timing and number of cryoablations performed.

	< 15 AFI cases	\geq 15 AFI cases	p*
Intervention timing (min)			
Procedure time	146.8 ± 50.0	78.1 ± 40.2	0.0001
Fluoroscopy time	32.7 ± 18.3	24.4 ± 11.0	0.02
Cryo application time	59.3 ± 27.4	43.3 ± 22.1	0.02

AFI = atrial flutter. * Student's t-test.

Follow-up data at 3 months. All patients, who were successfully treated at intervention, underwent a follow-up EPS approximately 3 months post-intervention, to assess whether CTI block was maintained. Data were collected from 55 patients who were acutely successful with cryo energy at intervention. Figure 1 provides a graphical illustration of our chronic results. All 55 (100%) patients were free of symptoms of AFI at follow-up. In some patients antiarrhythmic medication in the form of 600 mg propafenone per day and 120 mg verapamil per day for paroxysmal episodes of atrial fibrillation.

Further ablation at the electrophysiological examination ensured complete CTI block was achieved in all patients. All patients were clinically monitored for 1 year after cryoablation to ensure they remained asymptomatic.

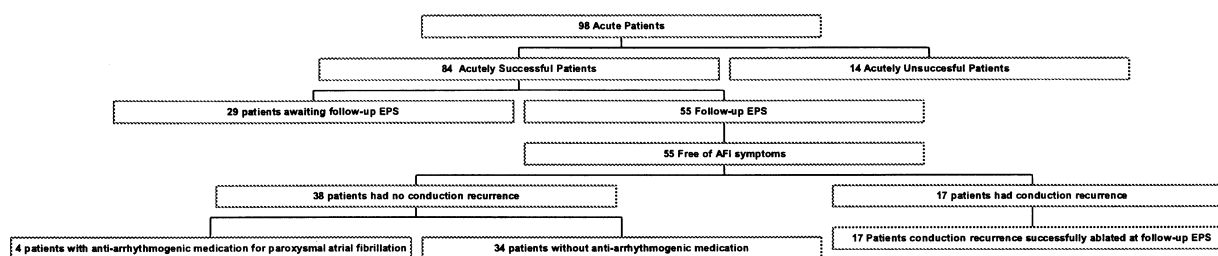


Figure 1. Acute and chronic outcome of patients receiving cryoablation for atrial flutter (AFI). EPS = electrophysiological study.

matic. No adverse events were reported in any patient between the ablation and the follow-up, nor at the follow-up electrophysiological examination.

Discussion

Introduction. Our group of 98 patients (92% common, 8% uncommon Afl) is representative of the general population of symptomatic patients, usually referred to expert centers for AFI ablation.

Several studies report success rates between 40 and 100% for RF ablation in AFI¹⁸⁻²⁰ but this study is the first on cryoablation in a large series of consecutive symptomatic AFI patients.

The aim of cryo catheter ablation was to create a complete and stable bidirectional CTI block, because it is accepted that AFI termination alone is not sufficient to avoid recurrence. Our initial experience on a limited number of patients showed that it was possible to cryoablate the CTI with success rates comparable with those achieved by RF and a number of advantages over other commonly used energy sources.

In this report, we have shown that following our initial learning experience of 14 common AFI patients, our success rates with cryo energy application for AFI were clinically and statistically significantly improved from 10 (71.4%) of 14 patients to 70 (92.1%) of 76 patients with common AFI. It has been our experience that applying RF following failure of cryo energy did not increase the likelihood of creating bidirectional isthmus block.

Cryoablation. Measuring time to effect during our so-called “test freeze” allowed us to assess the effect of cryo energy on the electrical conduction system at a potential site. If CTI block was observed with a time to effect of < 60 s, we moved to ablation. If no electrophysiological effect was observed, a new site was chosen and time to effect measured. We regularly used this feature in our patient series in order to identify the correct site for ablation and this was one of the reasons for the statistically significantly reduced procedure and fluoroscopy times in late versus early patients, as test freezes were not incorporated into the cryoablation protocol in early cases. In general, a suitable site usually had a time to effect of approximately 20 s.

Procedure times for cryoablation were very similar to those previously reported for high powered RF abla-

tion of common AFI, whereas fluoroscopy times were much reduced, 26 ± 13 min for cryo, compared with a range between 54 ± 26 , 36 ± 23 and 40 ± 16 min reported for three different catheter ablation technologies in a group of patients with common AFI¹.

AFI ablation with RF is often very painful, possibly because the ablation site is highly innervated and close to the CS os. The use of cryo energy has allowed us to ablate around the CS os without causing pain in patients receiving only mild sedation confirming the results of Timmermans et al.¹⁴, in a small number of patients, whose technique involved creating a complete flutter line. This allows patients to remain calm throughout the procedure.

Acute success in our patient group was statistically significantly higher ($p = 0.01$) in patients with common AFI compared with uncommon AFI. We postulate that uncommon AFI is more difficult to ablate because the critical isthmus may originate in the left atrium but the activation pattern in the right atrium mimics that of common right AFI.

The proof of a bi-directional conduction block in the CTI remains a critical issue in the confirmation of a successfully ablated AFI. Although, the literature reports unidirectional or rate dependent conduction blocks, in more than 31% of the patient population with RF, this was not observed with cryo in our experience^{3,17}. This can support two hypotheses:

- 1) the area where we placed the cryo lesion was more critical compared with the standard conventional isthmus lesion. Our technique did not involve creating a complete flutter line;
- 2) cryo produced a lesion more likely to result in bidirectional block than a conventional RF lesion.

These are discussed below.

Technique. The established method for ablation of Afl is to deliver temperature controlled sequential, point by point RF application to achieve complete isthmus block by drawing a continuous line¹.

This technique was based on the belief that the reentrant circuit is usually located in the right atrium and passed through the CTI between the inferior vena cava and tricuspid valve annulus. Our experience, however, has demonstrated that a conventional “flutter line” is not necessary to produce complete CTI block with cryo energy. We developed our new method following observations during early cryoablation procedures where AFI

termination appeared prior to complete CTI block, frequently with a time to effect of approximately 20 s at -75°C. With the combination of anatomical and ECG information, we tried to approach AFL ablation from a different perspective.

Our practice is to perform a test freeze on the inferior rim of the CS os. This is done under fluoroscopy guidance alone, because we were unable to find any specific target electrogram through the ablation catheter to differentiate a successful site from an unsuccessful one. When a site with a short time to effect was found during the test freeze, the same site was cryoablated.

In our experience, this critical area was frequently located in the inferior rim of the CS os. Waki et al.²¹ described the non-uniform trabecular pattern with abundant crossovers and interlacing, which exists in the normal heart, particularly in the zone immediately inferior to the CS os.

They concluded that the potential for conduction delay is present in the vast majority of normal hearts. We postulate that the CS os is similar to the pulmonary veins i.e. muscle sleeves provide an anatomical route for non-uniform conduction to the atrium. We hypothesize that automatic activity originating in the CS, passes into the right atrium via these muscle sleeves in the CS os and provides the trigger required for initiating AFL. The pathophysiology may be the same as the pulmonary veins, however, the anatomy of the right atrium, with the cristae terminalis forming a natural line of block, ensures that AFL and not atrial fibrillation results from premature beats.

As mentioned earlier, in our experience, AFL termination was usually observed within the first 20 s of cryo application and without creating complete CTI block. The short time to effect may indicate that the critical target area is very superficial and readily ablated. This in turn supports the hypothesis that the automatic trigger may originate in the CS. The CS is a thin structure and hence transmural with cryo energy should be readily attained. We postulate that by ablating the inferior rim of the CS os, the pathway for a premature beat to enter the right atrium is lost and/or the tissue producing the premature beat is destroyed. In the 17 (30.9%) patients who had reconnection without the resultant AFL symptom recurrence at 3-month follow-up, we postulate that this may be due to the following factors:

a) the cryo lesion did not cause permanent cell destruction across the entire CTI. Instead, cryo energy killed all cells exposed to temperature < 5°C but in areas between each site some cells remained at or above 5°C. These cells experienced a hypothermic reaction, which altered their electrical activity, but following rewarming the target cell survival ensured the linear block made during the ablation procedure was not quite complete;

b) a very rapid firing focus is located in this critical area and provides a trigger for flutter. If this focus is ablated during the acute procedure, simultaneously with the creation of isthmus block, it is possible to have reconnection over the isthmus due to point A, but without the

firing focus, spontaneous AFL is not possible anymore hence, symptoms do not recur.

This supports our hypothesis that the critical target is a small focal area near the CS where weakness in the myocardium provides a route for the AFL circuit and allows premature atrial beats to enter the right atrium from the CS.

Cryo is particularly well suited to ablating around the CS os because of its focused, highly defined lesions. Moreover, our use of cryo energy has also shown that it is not necessary to create a complete CTI line because isthmus block has been achievable in our experience by attempting to isolate the inferior rim of the CS from right atrial tissue.

Conclusions

Acute success of cryo energy to ablate AFL in our entire series occurred in 84 (85.7%) of 98 patients, increasing to 74 (88.1%) of 84 patients when 15 or more procedures had been performed. Furthermore, with experience of 15 or more procedures the success for common AFL was 70 (92.1%) of 76 patients. There were no adverse events reported and, of special note, no incidence of cryo induced permanent atrioventricular block. No discomfort was experienced by any patient on cryo energy delivery.

At 3-month follow-up, all 55 acutely successful patients were free of symptoms of AFL. There was no conduction or symptom recurrence of AFL in 38 (69.1%) of 55 patients who were successfully treated at intervention with cryo energy, 34 (89.5%) patients without antiarrhythmic medication. However, 17 (30.9%) patients had conduction recurrence across the isthmus observed at EPS follow-up, which we presumed to be due to incomplete isthmus block.

The absence of symptoms in these 17 patients supports our hypothesis that a focal trigger from the CS is responsible for initiating AFL. The rationale is that once the focal trigger from the CS is ablated AFL cannot occur spontaneously. Recurrence of conduction in our group of AFL patients may be comparable with the recurrence of conduction observed for pulmonary veins.

Longer refractoriness and different anatomy in the right atrium compared with the left atrium may explain why conduction recurrence in the pulmonary veins is more likely to result in atrial fibrillation than the likelihood of conduction recurrence of the CS resulting in AFL. This hypothesis deserves further investigation

Cryo energy ablation of patients is a safe, efficacious and pain free treatment for AFL.

References

1. Marrouche N, Schweikert R, Saliba W, et al. Use of different catheter ablation technologies for treatment of typical atrial flutter: Acute results and long-term follow-up. *Pacing Clin Electrophysiol* 2003; 26: 743-6.

2. Chen J, de Chillou C, Basiouny T, et al. Cavotricuspid isthmus mapping to assess bidirectional block during common atrial flutter radiofrequency ablation. *Circulation* 1999; 100: 2507-13.
3. Cauchemez B, Haïssaguerre M, Fischer B, et al. Electrophysiological effects of catheter ablation of inferior vena cava-tricuspid annulus isthmus in common atrial flutter. *Circulation* 1996; 93: 284-94.
4. Poty H, Saoudi N, Abdel Aziz A, et al. Radiofrequency catheter ablation of type I atrial flutter: Prediction of late success by electrophysiological criteria. *Circulation* 1995; 92: 1389-92.
5. Poty H, Saoudi N, Nair M, et al. Radiofrequency catheter ablation of atrial flutter: Further insights into the various type of isthmus block. Application to the ablation during sinus rhythm. *Circulation* 1996; 94: 3204-13.
6. Camm J, Ward DE, Spurrell RA, et al. Cryothermal mapping and cryoablation in the treatment of refractory cardiac arrhythmias. *Circulation* 1980; 62: 67-74.
7. Dubuc M, Talajic M, Roy D, et al. Feasibility of cardiac cryoablation using a transvenous steerable electrode catheter. *J Interv Card Electrophysiol* 1998; 2: 285-92.
8. Skanes A, Dubuc M, Klein GJ, et al. Cryothermal ablation of the slow pathway for the elimination of atrioventricular nodal reentrant tachycardia. *Circulation* 2000; 102: 2856-60.
9. Riccardi R, Gaita F, Caponi D, et al. Percutaneous catheter cryothermal ablation of atrioventricular nodal reentrant tachycardia: efficacy and safety of a new ablation technique. *Ital Heart J* 2003; 4: 35-43.
10. Gaita F, Paperini L, Riccardi R, et al. Cryothermic ablation within the coronary sinus of an epicardial posterolateral pathway. *J Cardiovasc Electrophysiol* 2000; 13: 1160-3.
11. Lanzotti M, De Ponti R, Tritto M, et al. Successful treatment of anteroseptal accessory pathways by transvenous cryomapping and cryoablation. *Ital Heart J* 2002; 3: 128-32.
12. Gaita F, Haïssaguerre M, Giustetto C, et al. Safety and efficacy of cryoablation of accessory pathways adjacent to the normal conduction system. *J Cardiovasc Electrophysiol* 2003; 14: 825-9.
13. Kimman G-J, Szili-Torok T, Theuns D Et Al. Transvenous Cryothermal Catheter Ablation Of A Right Anteroseptal Accessory Pathway. *J Cardiovasc Electrophysiol*. 2001; 12, 1415-1417
14. Timmermans C, Ayers G, Crijns H, et al. Randomized study comparing radiofrequency ablation with cryoablation for the treatment of atrial flutter with emphasis on pain perception. *Circulation* 2003; 107: 1250-2.
15. Khairy P, Chauvet P, Lehmann J, et al. Lower incidence of thrombus formation with cryoenergy versus radiofrequency catheter ablation. *Circulation* 2003; 107: 2045-50.
16. Siegel S. Non parametric statistics for the behavioural sciences. International student edition. Kogakusha: McGraw-Hill Book Company, 1956.
17. Schumacher B, Pfeiffer D, Tebbenjohanns J, et al. Acute and long-term effects of consecutive radiofrequency application on conduction properties of the subeustachian isthmus in type I atrial flutter. *J Cardiovasc Electrophysiol* 1998; 9: 152-63.
18. Rodriguez LM, Nabar A, Timmermans C, et al. Comparison of results of an 8-mm split-tip versus a 4-mm tip ablation catheter to perform radiofrequency ablation of type I atrial flutter. *Am J Cardiol* 2000; 85: 109-12.
19. Saoudi N, Nair M, Abdel Azziz A, et al. Electrocardiographic patterns and results of radiofrequency catheter ablation of clockwise type I atrial flutter. *J Cardiovasc Electrophysiol* 1996; 7: 931-42.
20. Jaïs P, Shah D, Haïssaguerre M, et al. prospective randomized comparison of irrigated-tip versus conventional-tip catheters for ablation of common flutter. *Circulation* 2000; 101: 772-6.
21. Waki K, Saito T, Becker AE. Right atrial isthmus revisited: normal anatomy favors nonuniform anisotropic conduction. *J Cardiovasc Electrophysiol* 2000; 11: 90-4.

COMPARISON BETWEEN ELECTROANATOMIC MAPPING (CARTO®) AND MULTISLICE-COMPUTED TOMOGRAPHY VOLUME RENDERING RECONSTRUCTION FOR THE EVALUATION OF PULMONARY VEIN ANATOMY

Maurizio Del Greco, Maurizio Centonze*,
Alessandro Cristoforetti**, Giandomenico Nollo**,
Flavia Ravelli**, Lorena Gramegna, Marcello Disertori

*Electrophysiology Laboratory, Cardiology Unit, *Radiology Unit, S. Chiara Hospital, **Department of Physics, University of Trento, Trento, Italy*

Detailed knowledge of left atrium will assist in the development of techniques for ablative intervention and the importance of pulmonary vein anatomy to the success of atrial fibrillation ablation is now appreciated. CARTO is a non-fluoroscopic three-dimensional electroanatomic navigation system widely used in the last years for volume rendering reconstruction of left atrial anatomy for ablation. More recently multidetector helical computed tomography has been gaining a role in evaluating cardiac anatomy providing the necessary information for successful ablation. This study compares the results and the usefulness of three-dimensional left atrial reconstruction between CARTO and multidetector helical computed tomography, in a group of 9 patients with drug refractory atrial fibrillation who underwent pulmonary vein ablation.

Introduction

Atrial fibrillation (AF), the most frequently occurring sustained arrhythmia, may be initiated by ectopic beats that originate in the ostia of the pulmonary veins (PV). Radiofrequency catheter ablation (RFCA) of AF using a "PV approach" has emerged from being a highly experimental procedure performed in many electrophysiology laboratories¹⁻³. Independently of the different approaches proposed, the target of PV ablation remains the atriopulmonary venous junction that can be achieved only with precise, pre-procedural delineation of left atrial anatomy. Furthermore increasing evidence suggests that the risk of PV stenosis may be minimized and the success maximized by delivery of radiofrequency energy to the ostial portion of the PV⁴⁻⁸. Because fluoroscopy provides only limited information about the relationship between catheter positions and cardiac structures and is associated with radiation risk, other approaches to mapping may be beneficial.

CARTO® is a non-fluoroscopic three-dimensional electroanatomic navigation system that has been used in the last years for reconstruction of left atrial and PV anatomy for RFCA^{3,4}. More recently multidetector helical computed tomography (MDCT) is gaining a role in evaluating cardiac anatomy providing the necessary information for successful RFCA, including the number, location, angulation of PVs and their ostial branches unobscured by adjacent cardiac and vascular anatomy, and left atrial volume⁹⁻¹². In particular, the PV present an oblique course, variable branching and size that cannot be assessed with conventional angiography, so that multidimensional imaging is mandatory.

Although PV anatomy has drawn increasing attention from electrophysiologist no standardized methods for analysing left atrial and PV anatomy and assessing PV narrowing have been described. The aim of this study was to compare the results and the usefulness of three-dimensional PV reconstruction between CARTO and MDCT.

Methods

The study population consisted of 9 patients (9 men, mean age 56.9 year) who underwent RFCA of AF by use of a PV approach as previously described by Pappone et al.^{3,4}. Each patient had symptomatic drug-refractory paroxysmal or persistent AF. Mild hypertensive cardiopathy was detected in 1 patient while in the others echocardiogram examination was normal. After transseptal puncture electroanatomic mapping (CARTO) of left atrium and PV ostia was performed. Guided by the CARTO maps, all the patients underwent RFCA around the main ostia identified by use of cooled-tip catheter (Navi-Star Thermo-Cool®, Biosense Webster, Diamond Bar, CA, USA) until the complete electrical isolation of PV was demonstrated. Acute complications were not observed.

Subsequently, MDCT was performed in all the study patients: after 1 month in 6, after 2 months in 2 and after 4 months in 1 patient.

In our institution image acquisition was performed using 16-slice helical scanner with 420 ms gantry rotation (MX 8000 IDT® Philips Medical System, Eindhoven, The Netherlands). A single slice could be reconstructed from 180° of computed tomography data acquired during the X-ray tube rotation, thus achieving a temporal resolution of 210 ms for a 420 ms rotation time. An ECG was recorded during the continuous CT data acquisition and the data sets for each moment of time in the cardiac cycle were reconstructed by reference to the R-wave peak (retrospective gating). The parameters of the cardiac scan were the following: 16 × 0.75 mm collimation, 0.42 s rotation time, heart rate dependent table speed, 140 kV tube voltage, 400 mAs tube current. The scan time varied between 16-22 s depending on the size of the heart, covering the volume from the

heart base to the middle thoracic ascending aorta, during suspended respiration at end inspiration. During slice acquisition 125 ml of non-ionic iodinated contrast material (Iomeron 400®, Bracco, Milan, Italy) was administered intravenously using a double barrel power injector at a rate of 4-5 ml/s followed by a saline chaser bolus of 30 ml. The average Hounsfield Units (HU) in the left atrium region of interest were plotted against time and upon reaching a predefined threshold (100 HU) the helical cardiac scan was started automatically. After acquisition of helical computed tomography raw data retrospective ECG synchronized slices were reconstructed. Because data are acquired continuously the reconstruction window could be positioned at any point within the cardiac cycle but we chose only the 75% interval (end diastole) that showed less motion artefacts due to cardiac pulsatility. All post-processing analysis was performed using a dedicated modality work station (Mx View 5.0, Philips). The image data sets were analysed using multiplanar reconstruction (MPR), maximum intensity projection (MIP), virtual endoscopic images (Voyager) and volume rendering (VR) in addition to the axial source images. We measured the PV ostial main and perpendicular to this one diameters using MPR 3 mm thickness slab along the axial and coronal directions of the vessels; in this way we obtained a sagittal view of the ostium that was measured in the point of inflection between PV wall and left atrial wall. The number, directions and branching of the veins were assessed using source images, MPR, MIP, Voyager and VR techniques while the size of the left atrium was measured according the method of Ho et al.⁷ defining the transverse diameter as the distance between the midpoint of the right and left sides of the PVs in oblique axial MPR images and then the antero-posterior and longitudinal diameters measuring at the midpoint of the transverse diameter in oblique axial and sagittal MPR images. Left atrial volume was assessed in automatic way using three-dimensional reformatted images.

The main aim of MDCT analysis was the detection of PV stenosis or thrombosis. Then, for comparison, CARTO and MDCT data were used to evaluate in each patients:

- the number of PV ostia and branches;
- the direction of the PV;
- the main diameters and the volume of left atrium.

Preliminary results

In the study group no significant (> 50%) PV stenosis was found after RFCA. Only in one case a left inferior PV narrowing of about 20% was detected but the patient remains asymptomatic. As for the number of PV ostia and branches the MDCT seems better define than electroanatomic mapping (CARTO system) the PV anatomy and particularly PVs with very closed ostia as well as the ostia of very small vessel (e.g. right middle PV).

Conclusions

The preliminary results reveal the clinical value of 16-slice MDCT in facilitate the RFCA of AF arising from the PV thanks to the ability to quantitatively evaluate the number, size, and shape of the vessels. This information is useful in ascertaining that all the PV orifices are evaluated during the procedure and selecting an appropriately ablation strategy. Besides, MDCT plays an important role providing a quantitative assessment of the location, shape and severity of PV stenosis after RFCA procedure.

Acknowledgments

We gratefully thank Dr. Massimiliano Marini for his relevant support in the data collection and analysis.

References

1. Haissaguerre M, Jais P, Shah DC, et al. Spontaneous initiation of atrial fibrillation by ectopic beats originating in the pulmonary veins. *N Engl J Med* 1998; 339: 659-66.
2. Haissaguerre M, Jais P, Shah DC, et al. Electrophysiological end point for catheter ablation of atrial fibrillation initiated from multiple pulmonary venous foci. *Circulation* 2000; 101: 1409-17.
3. Pappone C, Rosanio S, Oreto G, et al. Circumferential radiofrequency ablation of pulmonary vein ostia: a new anatomic approach for curing atrial fibrillation. *Circulation* 2000; 102: 2619-28.
4. Pappone C, Oreto G, Rosanio S, et al. Atrial electroanatomic remodeling after circumferential radiofrequency pulmonary vein ablation: efficacy of an anatomic approach in a large cohort of patients with atrial fibrillation. *Circulation* 2001; 104: 2539-44.
5. Arentz T, Jander N, von Rosenthal J, et al. Incidence of pulmonary vein stenosis 2 years after radiofrequency catheter ablation of refractory atrial fibrillation. *Eur Heart J* 2003; 24: 963-9.
6. Dill T, Neumann T, Ekinici O, et al. Pulmonary vein diameter reduction after radiofrequency catheter ablation for paroxysmal atrial fibrillation evaluated by contrast-enhanced three-dimensional magnetic resonance imaging. *Circulation* 2003; 107: 845-50.
7. Ho SY, Sanchez-Quintana D, Cabrera JA, et al. Anatomy of the left atrium: implications for radiofrequency ablation for atrial fibrillation. *J Cardiovasc Electrophysiol* 1999; 10: 1525-33.
8. Kato R, Lickfett L, Meininger G, et al. Pulmonary vein anatomy in patients undergoing catheter ablation of atrial fibrillation. *Circulation* 2003; 107: 2004-10.
9. Lawler LP, Corl FM, Fishman EK. Multi-detector row and volume rendered CT of the normal and accessory flow pathways of the thoracic systemic and pulmonary veins. *Radiographics* 2002; 22: S45-S60.
10. Lacomis JM, Wigginton W, Fuhrman C, et al. Multi-detector row CT of the left atrium and pulmonary veins before radio-frequency catheter ablation for atrial fibrillation. *Radiographics* 2003; 23: S35-S48.
11. Perez-Lugones A, Schwartzman PR, Schweinkert R, et al. Three-dimensional reconstruction of pulmonary veins in

patients with atrial fibrillation and controls: morphological characteristics and different veins. *Pacing Clin Electrophysiol* 2003; 26(Part I): 8-15.

12. Schwartzmann D, Lacomis J, Wigginton G. Characterization of left atrium and distal pulmonary vein morphology using multidimensional computed tomography. *J Am Coll Cardiol* 2003; 41: 1349-57.

EPICARDIAL ABLATION OF ATRIAL FIBRILLATION

Angelo Graffigna

Cardiac Surgery Unit, S. Chiara Hospital, Trento, Italy

Surgical treatment of atrial fibrillation (AF) is no longer a pure adjunct to cardiac surgery operations, but a really due medical act owing to several considerations.

Surgical outcome is more favorable in patients with sinus rhythm due to better hemodynamics¹. Oral anti-coagulants can be avoided in elderly patients or with co-pathologies that could be potentially worsened.

For these reasons, cardiac surgical techniques have been developed for the treatment of this too often overlooked arrhythmia.

The original techniques developed were basically:
 • *corridor procedure* as described by Defauw et al.², that was soon abandoned due to too heavy hemodynamic imbalance;

• *atrial isolation* as described by Graffigna³, which eminently consisted in a left sided "corridor procedure", and that allowed recovery of hemodynamic function of right atrium but left a potentially fibrillating left one;

• *Maze procedure* as described by Cox⁴, that was based on experimental evidence that AF could not be mapped and ablated and that the only solution was to create a "Maze" along which atrial activation was allowed to proceed.

Maze procedure as originally described was applied in association with valve operations with success rates up to 90%⁵, but surgical impact of such a mighty additional procedure was considered unacceptable in most cases and blunted the widespread use of this technique.

Of these procedures, the Maze was definitely accepted as the "stem" concept, from which several modifications were performed, in order to obviate the implicit complications of the procedure, and according to different principles:

• *efforts to address specific anatomical and pathogenetic foci of onset of AF:*

- intuitive surgical addresses brought to development of left- or right-sided Maze procedures due to the belief that in mitral valve disease or atrial septal defects AF was due to enlargement of a single atrium^{6,7};

- electrophysiological findings showed that the pul-

monary vein ostia could originate bursts of extrastimulably so that AF could be initiated and maintained⁸;

• *efforts to replace surgical incisions with physically produced atrial lesions*: surgical incisions required time to be produced and sutured, carried the risk of bleeding and implied destruction and stiffening of a great amount of atrial tissue. For this reason, physical energy delivery sources were used in order to create the equivalent of a surgical incision, i.e. an electrical block:

- radiofrequency was the first to be adopted, being easily available in electrophysiology laboratories⁹, and was delivered with home-made devices¹⁰, or more sophisticated products with saline-irrigated tips¹¹. Further modifications involved multi-point delivery system in order to reduce application time¹² and bipolar delivery devices^{13,14}. Several experiences were developed with this technique, and results of sinus rhythm recovery up to 76% were achieved^{15,16};

- ultrasounds have been described for intraoperative ablation of AF^{17,18}, but unreliable results in case of thickened atria has limited their use;

- microwaves showed to be a very flexible tool for intraoperative AF ablation, due to ease of delivery, avoidance of indifferent electrodes, and minimization of inconvenient due to “charring” and “popping” as observed with radiofrequency¹⁹. Several experiences developed and showed consistent results up to 91%²⁰.

Due to these encouraging results, a further step was made when closed-heart, epicardial ablation of AF was achieved²¹.

Technical details are not redundant in order to understand the feasibility of this technique. With the epicardial approach, individual isolation of the pulmonary veins is difficult and a global isolation of the posterior left atrium is advisable; barring lesions onto the mitral and tricuspid valves must be performed from outside, after previous dissection of the atrioventricular fat pad; obliteration of the right and left atrial appendages must be performed by means of purse-string sutures (Fig. 1).

Epicardial ablation of atrial fibrillation has been performed in valvular heart operations by means of radiofrequency, with an additional cross-clamping time of about 10 min²² an efficacy of 77%²³, although some

concern has arisen about completeness of lesions for tissues thicker than 4 mm²⁴.

The step towards epicardial, beating heart ablation of AF was made in 2001, when Graffigna described in a movie the use of microwaves for epicardial ablation of AF with beating heart myocardial revascularization²⁵, and soon other descriptions were made by Mazzitelli et al.²⁶, Athanasiou et al.²⁷, Maessen et al.²⁸.

Inherent results are encouraging and deserve adequate attention:

- operative mortality for the procedure is definitely \leq the standard procedure, thus meaning that the procedure does not carry additional risk;
- sinus rhythm recovery is not inferior to the standard Maze procedure, thus meaning that epicardial approach is not only feasible but effective (Table I).

Such considerations should be kept in mind when dealing with a patient with coronary artery disease and atrial fibrillation. Such patients typically show advanced coronary artery disease, possibly some degree of mitral valve incompetence, degenerated left ventricular function and poor prognosis if AF persists. More often, surgical indication is in doubt due to poor cardiac function, and additional problems are given by high risk of pulmonary or peripheral embolism.

Our address is to treat these patients by means of associated myocardial revascularization and Maze procedure on a beating heart. We do not address mitral valve incompetence at first, provided an adequate amount of viable myocardium is documented at nuclear scan, as it is common to see regression of mitral valve incompetence after revascularization, and as it is possible to treat mitral valve insufficiency later, when adequate recovery has taken place in cardiac function.

Table I.

	No. patients	Operative mortality (%)	Sinus rhythm (%)
Graffigna ²⁵	8	0	75
Mazzitelli et al. ²⁶	24	0	86

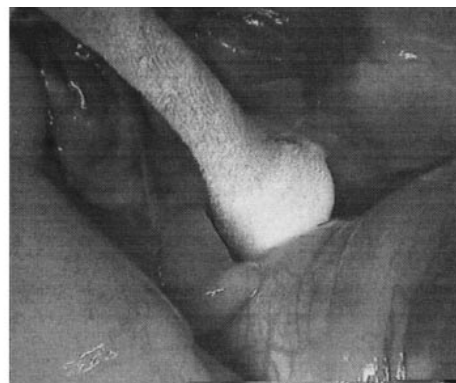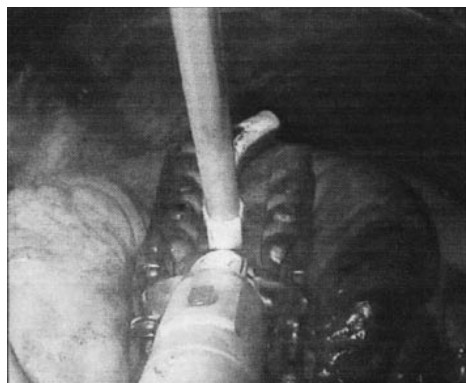


Figure 1. Microwave and cryoablation in epicardial ablation.

Epicardial ablation of AF is not only a present and viable option for treating "surgical" AF, but could represent a formidable alternative to endocardial catheter ablation under the form of an endoscopic procedure.

References

- Obadia JF, el Farra M, Bastien OH, Lievre M, Martelloni Y, Chassignolle JF. Outcome of atrial fibrillation after mitral valve repair. *J Thorac Cardiovasc Surg* 1997; 114: 179-85.
- Defauw JJ, Guiraudon GM, van Hemel NM, Vermeulen FE, Kingma H, de Baker JM. Surgical therapy of paroxysmal atrial fibrillation with the "corridor" operation. *Ann Thorac Surg* 1992; 53: 564-71.
- Graffigna A. Left atrial isolation associated to mitral valve operations. *Ann Thorac Surg* 1992; 54: 1093-8.
- Cox JL. The surgical treatment of atrial fibrillation. IV. Surgical technique. *J Thorac Cardiovasc Surg* 1991; 101: 584-92.
- Isobe F. The outcome and indications of the Cox Maze III procedure for chronic atrial fibrillation with mitral valve disease. *J Thorac Cardiovasc Surg* 1998; 116: 220-7.
- Sueda T, Nagata H, Shikata H, et al. Simple left atrial procedure for chronic atrial fibrillation associated with mitral valve disease. *Ann Thorac Surg* 1996; 62: 1796-1800.
- Minzioni G. Surgical treatment of atrial fibrillation in patients with atrial septal defect. *J Cardiovasc Surg* 1992; 33: 22.
- Haissaguerre M, Jais P, Shah DC, et al. Spontaneous initiation of atrial fibrillation by ectopic beats originating in the pulmonary veins. *N Engl J Med* 1998; 339: 659-66.
- Melo J, Adragão P, Neves J, et al. Surgery for atrial fibrillation using intraoperative radiofrequency ablation. *Rev Port Cardiol* 1998; 17: 377-9.
- Graffigna A. Intraoperative radiofrequency ablation of atrial fibrillation in patients undergoing mitral valve surgery. In: proceedings of the World Symposium on Heart Valve Disease. London UK, June 11-14, 1999: 195.
- Kharg K. Saline-irrigated, cooled-tip radiofrequency ablation is an effective technique to perform the Maze procedure. *Ann Thorac Surg* 2001; 72: S1090-S1095.
- Prasad SM, Maniar HS, Diodato MD, Schuessler RB, Damiano RJ Jr. Physiological consequences of bipolar radiofrequency energy on the atria and pulmonary veins: a chronic animal study. *Ann Thorac Surg* 2003; 76: 836-42.
- Gillinov A. Atricure bipolar radiofrequency clamp for intraoperative ablation of atrial fibrillation. *Ann Thorac Surg* 2002; 74: 2165-8.
- Prasad SM, Hersh S, Maniar, et al. Physiological consequences of bipolar radiofrequency energy on the atria and pulmonary veins: a chronic animal study. *Ann Thorac Surg* 2003; 76: 836-42.
- Sie HT, Beukema WP, Ramdat Misier AR, et al. The radiofrequency modified maze procedure. A less invasive surgical approach to atrial fibrillation during open-heart surgery. *Eur J Cardiothorac Surg* 2001; 19: 443-7.
- Williams MR, Stewart JR, Bolling SF, et al. Surgical treatment of atrial fibrillation using radiofrequency energy. *Ann Thorac Surg* 2001; 71: 1939-44.
- Graffigna A. Different energy sources for ablation of atrial fibrillation in patients undergoing mitral valve surgery. *Progress in Clinical Pacing* 2000. Roma: December 5-9, 2000: A99.
- Natale A, Pisano E, Shewchik, et al. First human experience with pulmonary vein isolation using a through-the-balloon circumferential ultrasound ablation system for recurrent atrial fibrillation. *Circulation* 2000; 102: 1879-86.
- Graffigna A. L'utilizzo di diverse forme di energia per il trattamento della fibrillazione atriale in corso di chirurgia mitralica. *Ital Heart J* 2000; 1 (Suppl 6): 46.
- Schuetz A, Schulze CJ, Sarvanakis KK, et al. Surgical treatment of permanent atrial fibrillation using microwave energy ablation: a prospective randomized clinical trial. *Eur J Cardiothorac Surg* 2003; 24: 475-80.
- Graffigna A. Surgery for atrial fibrillation: the microwaves epicardial approach. *G Ital Aritm Elettrostim* 2002; 5: 234-6.
- Raman J, Ishikawa S, Power JM. Epicardial radiofrequency ablation of both atria in the treatment of atrial fibrillation: experience in patients. *Ann Thorac Surg* 2002; 74: 1506-9.
- Benussi S, Nascimbene S, Agricola E, et al. Surgical ablation of atrial fibrillation using the epicardial radiofrequency approach: mid-term results and risk analysis. *Ann Thorac Surg* 2002; 74: 1050-7.
- Thomas SP, Guy DJ, Boyd AC, Eipper VE, Ross DL, Chard RB. Comparison of epicardial and endocardial linear ablation using handheld probes. *Ann Thorac Surg* 2003; 75: 543-8.
- Graffigna A. Off-pump CABG and maze procedure by means of microwaves and cryoablation. *EACTS/ESTS Joint Meeting*. Lisbon, Portugal, September 16-19, 2001.
- Mazzitelli D, Park CH, Park KY, Benetti FJ, Lange R. Epicardial ablation of atrial fibrillation on the beating heart without cardiopulmonary bypass. *Ann Thorac Surg* 2002; 73: 320-1.
- Athanasios T, Kumar P, Al-Ruzzeq S, et al. Expanded use of suction and stabilization devices in cardiothoracic surgery. *Ann Thorac Surg* 2003; 76: 1126-30.
- Maessen JG, Nijs JF, Smeets JL, Vainer J, Mochtar B. Beating-heart surgical treatment of atrial fibrillation with microwave ablation. *Ann Thorac Surg* 2002; 74: 1307S-1311S.

SURGICAL TREATMENT OF CHRONIC ATRIAL FIBRILLATION WITH RADIOFREQUENCY ABLATION DURING MITRAL VALVE SURGERY. OUR EXPERIENCE AND CONSIDERATION

Alessandro Frigiola, Piero Proietti,
Carlo DeVincentiis, Alessandro Giamberti,
Lorenzo Menicanti

*Division of Cardiac Surgery, Istituto Policlinico San Donato,
San Donato Milanese (MI), Italy*

Atrial fibrillation (AF) is a common cardiac rhythm disorder affecting millions of people worldwide. Since the early 1980's, several procedures have been developed for treating AF surgically. Today's standard is the Maze III procedure. Recently to simplify and to reduce the risk of the classic Maze procedure, without modifying the fundamental concept of original technique, many alternative procedures have been developed.

At our Institute from November 2002 we stopped to perform the classic Maze procedure and we started to use an irrigated radiofrequency device to create the majority of the required lesions. We have treated 15 consecutive patients (6 males, 9 females, mean age 68 years), suffering from mitral valve disease with AF for more than

3 months. Eight patients underwent mitral valve replacement. In the others a mitral valve repair was performed. In all patients a left atrial irrigated radiofrequency modified Maze was performed.

The inclusion criteria were: the indication for mitral valve surgery associated with a documented AF prior hospitalization, age > 18 years. Patients were in NYHA functional class III-IV. All of them were taking antiarrhythmic drugs (beta-blockers, K-channel blockers or Na-channel blockers, digoxin). All of them were taking anticoagulant or antiplatelet drugs.

There were no in-hospital deaths. In all patients, except 2, the sinus rhythm was restored at the hospital discharge. In 1 patient an AV sequential pacemaker was

implanted. To evaluate the left atrial contraction a Doppler echocardiography was performed before the discharge. Follow-up was performed at 3-6 and 12 months. Mean follow-up was 5 months. Four patients had a recurrence of AF. One patient needed a readmission to the hospital for electrical cardioversion. In all of them antiarrhythmic therapy was restored. No thromboembolic events were registered.

According to other larger series recently published, ablation with radiofrequency has become an efficient option for the treatment of chronic AF, even when associated with mitral valve surgery. In our smaller series we are encouraged to continue to use this technique because of its safety and easy application, giving good results also in the mid term.